

CASE REPORT

SICKLE CELL DISEASE IN HAZARA

Shaheen Pervez Khan, Jahangir A. Khan and M.A. Khaliq

Sickle cell disease is group of inherited disorders of haemoglobin formation. It includes sickle cell anaemia (Hb SS), Haemoglobin SC disease (HbSC) and Sickle Cell B-Thalassaemia (HbS/B-Thal). Sickle Cell anaemia (HbSS) is most common and severe which is 0.3% to 1.3% in American blacks while Sickle Cell B-Thal is 0.04%.¹

Sickle Cell B-Thalassaemia is double heterozygous state for Hb-S and the B-Thalassaemia is double heterozygous state for Hb-S and the B-Thalassaemia genes. It occurs mainly in persons of Greek, Italian descent and in Negroes.² In general it resembles sickle-cell anaemia, but tends to be less severe. There are two types of sickle cell B-Thalassaemia, one is B+thalassaemia which is characterized by incomplete suppression and B⁰-thalassaemia by complete absence of B-chain synthesis.

It is some time difficult to distinguish between sickle-cell anaemia and S/B⁰ thalassaemia. The pattern of the B⁰ type closely resembles that of sickle-cell anaemia and the electrophoretic differential diagnosis usually depends on the demonstration of an increased Hb-A2 level³ in the former condition. Examination of other family members for evidence of the thalassaemia gene should be undertaken in all putative cases of sickle-cell anaemia to avoid diagnostic error. The finding of an enlarged spleen in an older patient may be useful in differential diagnosis because splenomegaly is much more likely to be encountered in patients (>6 years) with S/B⁰ thalassaemia than in homozygous sicklers. Hypochromia and microcytosis of erythrocytes is usually established by the age of one year. S/B⁰ thalassaemia tends to be more severe than S/B⁺ thalassaemia. S/B⁰ resembles more, clinically, with sickle-cell anaemia as in ocular and bony manifestations, pain, accelerated haemolysis and vasoocclusion, long term anaemia, acute chest syndrome (Pneumonia or pulmonary infarction or both), and fever.⁴ A case report of sickle-cell B⁰-thalassaemia is presented here. The patient was admitted in the DHQ Hospital, Abbottabad.

CASE REPORT

A blood specimen was received for sickling test and Hb Electrophoresis at PMRC Research Centre, Ayub Medical College, Abbottabad. Clinical history described that 4 years old child was admitted in June, 1990 in Paediatrics Ward of DHQ Hospital, Abbottabad with complaints of pain in right forearm, elbow joint, left leg, anaemia and fever. It was treated as a case of acute osteomyelitis. The blood CP report showed Hb 5.8 g/dl, TLC 9,600/cm, poly 61% lympho 36% Eos 1% Mono 2%. The patient was transfused one pint of blood on 18-6-1990 and was treated with antibiotics. He became well after 6 days but again developed the pain and swelling in right arm, low grade fever without sweating. The left leg was swollen and tender but no history of trauma. The blood CP was done again which showed Hb 7.0 g/dl, TLC, 12,4000, poly 62%, lympho 36% Eos 1%. The blood was also sent for culture and sensitivity.

From: PMRC and Ayub Medical College, Abbottabad.

SHAHEEN, P.K. Research Officer (PMRC).

JAHANGIR, A.K. Ph.D.(U.K) Principal Research Officer (PMRC).

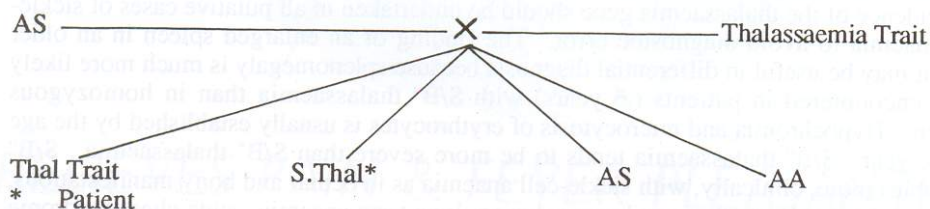
KHALIQ M.A. MRC Path (U.K) Head of Pathology Deptt. Ayub Medical College, Abbottabad.

The investigations were carried out at PMRC-Laboratory and patient was found to sickle-cell B^o-thalassaemia (S-B^o) and blood culture showing growth of Streptococcus pneumoniae. The family history of patient was positive. The patient's sister died at the age of 7 months. Parents of patient were also investigated for haemoglobinopathies. The mother was found to be sickle-cell Trait (Hb-AS), while father was B-thalassaemia trait. The child was treated symptomatically and the parent were informed. Their electrophoretic phenotypes are following. (Table-1).

Table1 : Electrophortic phenotypes patrn of patient and his parents.

Patient	Disorder	Haemoglobin %			
		A	A2	F	S
	Sickle-Cell B-thalassaemia (S-B ^o)	0	4.8	32.8	62.4
Mother	Sickle-Cell trait (AS)	60.8	2.6	1.0	35.6
Father	B-thalassaemia trait	93.2	5.6	1.2	0

The patient inherited the disease genetically as shown in following diagram:



DISCUSSION

It is concluded that although double heterozygous (S/B thalassaemia is rare in our population but incidence is not exempted. Sickle Cell B-thalassaemia is severe haemoglobinopathy, such children should be admitted to hospital immediately for confirmation of diagnosis and transfusion for early treatment. They should be looked at special clinic or by paediatrician or haematologist with particular interest in the condition. All anaemic persons and couples must be screened for haemoglobinopathies. The couples who are both heterozygous should be offered foetal diagnosis at 8 week of pregnancy, if foetus is found to be homozygous, termination of pregnancy should be recommended at 20 weeks or as soon as possible. A haemoblobinopathy screening programme must be done by health authority for accurate diagnosis, counselling, preventive medicine and education. It is fact that increase in maternal and fetal morbidity and mortality has frequently been associated with sickle cell disease, so couple at risk of having off spring must be screened in priority. An education programme is also necessary for people having thalassaemia/haemoglobinopathies for their future betterment.

REFERENCES

1. Robert, M. Schmidt. Laboratory diagnosis of haemoglobinopathies. JAMA 1973; 224(9):1278.
2. Serjeant, G.R. et al. The Clinical features of sickle cell B-thalassaemia in Jamaica. Brit J. Haemat 1973; 24,19.
3. Franklin, H. Bunn et al. Haemoglobinopathies (Major Problems in internal medicine; V.12) W.B. Saunders Company London. 1977; P.179-181.
4. Haemoglobinopathies and allied disorders: Report of a WHO scientific group. WHO Tech Rep Ser 1965; 338: 1-40.