

## AESTHETIC OUTCOME OF SLIDING ISLAND FLAP FOR RECONSTRUCTION OF CHEEK AFTER TUMOUR ABLATION

Hidayatullah, Obaidullah, Mohammad Asif\*, Mohammad Tahir, Mohammad Aslam  
Department of Plastic and Reconstructive Surgery, PGMI Hayatabad Medical Complex Peshawar and \*Department of ENT, Ayub Medical College, Abbottabad

**Background:** Skin cancer is the most common malignancy in humans and the incidence continues to rise. Facial reconstruction after cutaneous tumour ablation is a challenging job and needs thorough knowledge of the anatomy and physiology of face skin, biomechanics of skin and muscles, design of local flaps and their blood supply. The objective of this study was to report the aesthetic results of sliding island flap on the cheek. **Methods:** This study was carried in the department of Plastic and Reconstructive Surgery Postgraduate Medical Institute Hayatabad Medical Complex Peshawar from March 2001 to February 2004. Forty patients with age 50-70 years having Basal Cell Carcinoma on infraorbital and malar area of the cheek were taken for the study. Tumors were excised with safe margins and defects restored with sliding island flap. This flap is based on subcutaneous vertical pedicle that vascularizes the skin island through sub dermal plexus. Patients were regularly followed up with preoperative and postoperative photography. Final aesthetic results were analyzed after six months. **Results:** Good symmetry of cheek was achieved. There was no noticeable scarring. Flap necrosis was not seen in any patient. Only one patient had mild ectropion of the lower eyelid (2.5%) that did not need any revisional surgery. **Conclusions:** Relatively bigger defects of the cheek can be easily covered with this flap with preservation of cosmesis and without any distortion in the symmetry of the face. **KEY WORDS:** Cheek, Tumour, Reconstruction, Sliding island flap.

### INTRODUCTION

Skin cancer is the most common malignancy occurring in humans.<sup>1</sup> In most cases it requires surgical ablation and three dimensional reconstruction. Cheek is one of the most important aesthetic units of the face.<sup>2</sup> Reconstruction should recreate the natural contours and landmarks of the cheek in a way that restores symmetry, proportion and balance. There should be minimum noticeable scarring. Local flaps provide the foundations for such reconstruction.<sup>3</sup> Following resection of the tumour a number of reconstructive options are available. Local flaps are in the immediate vicinity of the defect. These flaps provide rapid reconstruction using the donor site tissue with excellent colour and texture match, reliable blood supply and good function.<sup>2, 4, 5</sup>

For less extensive defects of the cheek we have good experience with vertically pedicled Sliding Island Flap. This flap has been well elaborated in literature. It is the utilization of nearest possible tissue with the same colour and texture. The flap has widely based pedicle, which incorporates venous and lymphatic drainage.<sup>6,7</sup> Therefore postoperative undesirable edema does not develop.<sup>6</sup> The skin island is nourished by subcutaneous vessels through sub dermal plexus. The flaccidity of subcutaneous tissue determines the degree of advancement of the flap.<sup>6</sup> The advantages of the flap are easy and rapid dissection, reliable blood supply, easy closure of donor area and unnoticeable scarring. The objective

of the study is to report the aesthetic results of sliding island flap on the cheek.

### MATERIAL AND METHODS

This study was carried out over a period of three years from March 2001 to February 2004 in the Department of Plastic and Reconstructive Surgery Postgraduate Medical Institute Hayatabad Medical Complex Peshawar.

Forty patients with Basal Cell Carcinoma on the infraorbital and malar region of the cheek were taken for the study. Patients' age ranged from 50 to 70 years. Size of the lesions ranged from 2.5 cm to 4.5 cm in diameter. Thorough physical examination was carried. CT scan was done in three patients to know the deep extent of the lesions. Preoperative photographs were taken. Only patients with BCC on the cheek were included in the study. Defect on the cheek due to other lesions like trauma, nevi and scars have been excluded. Effects of the surgery were noted on the structures of the face including any distortion of upper lip, any nasal deviation, lower eyelid ectropion, ugly scarring and symmetry of the face on emotional expression.

Tumor was excised with safe margins and depth. Specimens were sent for histopathology and clearance of the margins. The procedure was performed under local anesthesia - lidocaine with adrenaline 1:100000. Haemostasis was secured with bipolar coagulation. The flap was marked and raised adjacent to the defect.

The flap length/defect diameter ratio ranged between 2:1 and 3:1 as suggested by Pontes et al.<sup>6</sup> The incisions were just deep to subcutaneous tissue and were placed when possible in the natural crease lines considering and respecting the aesthetic units of the face as advised by Kalus and Zamora.<sup>7</sup> The undermining of the flap was loosening of the deep tissue with blunt dissection and preservation of vascular supply. The advancing edge of the flap was exclusively made free of the underlying tissue just beneath the sub dermal plexus. The flap was advanced to its new location. The dermis of the flap near its advancing edge was stitched to the periosteum of the underlying bone with a non absorbable suture using Mitek Anchor System of flap fixation to facial bones.<sup>8</sup> These few stitches keep the flap stay at the new position and prevent traction on the lower eyelid. Finally the flap was stitched with vicryl 4/0 and prolene 6/0 on atraumatic cutting needle in two layers. The distal donor area was closed as V-Y. Patients were followed up at 5 days for removal of stitches, 2 weeks, 6 weeks and then every 3 months as per protocol. Postoperative photographs were taken on each follow up visit and thorough physical examination carried for any recurrence of the tumour. Final aesthetic results were analyzed after six months. The parameters for cosmesis after flap surgery were effect on the lower eyelid (ectropion), nasal deviation, upper lip distortion, ugly scarring and cheek distortion in static position and on emotional expression.

## RESULTS

The sliding island flap based on vertical subcutaneous pedicle which vascularizes the skin island through sub dermal plexus was used in forty patients for cheek reconstruction after oncologic resections. Twenty-five (62.5%) were men and fifteen (37.5%) were women. Patients were 50-70 years of age. All lesions were basal cell carcinoma of different subtypes and were located on the infraorbital or malar region of the cheek. All patients were operated on an outpatient basis-as day cases. The operative time was 45-60 minutes. Hospital stay was 1-3 hrs.

Flap necrosis and edema was not seen even in a single patient (0%). Infection occurred in one patient (2.5%) which was managed conservatively. Lower eyelid ectropion (mild) was noted in one patient (2.5%) who did not need any revisional surgery. Tumour recurred in two patients (5%) who needed surgery and biopsy again. Nasal deviation and upper lip distortion was not noted in any patient (0%). Wounds healed uneventfully with fine unnoticeable scar (Fig. 2e). Surgeon and all patients were satisfied with the results. There was no

distortion of the cheek on emotional expression. Symmetry of the face was achieved in all patients. The only complaint by one patient was that the operated cheek looks younger than the non operated.

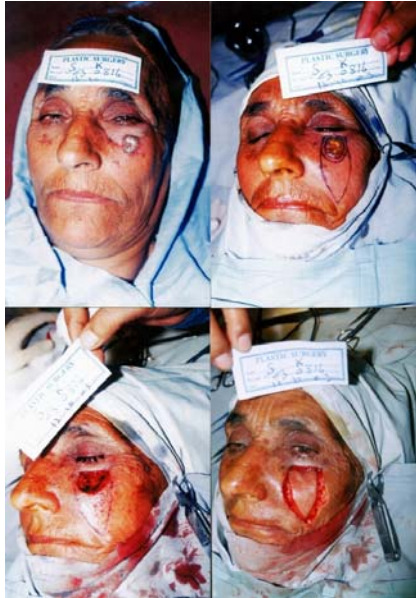**Table-1 Aesthetic Results of Sliding Island Flap for cheek Reconstruction.**

Flap viability	40 (100%)
Nasal deviation	0 (0%)
Upper lip distortion	0 (0%)
Infection	1 (2.5%)
Ectropion	1 (2.5%)
Tumour recurrence	2 (5%)

## DISCUSSION

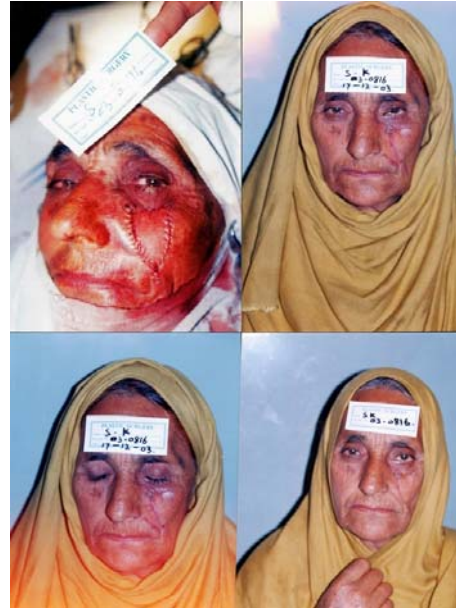Among the local flaps available for cheek reconstruction vertically pedicled sliding island advancement is commonly practiced. Several modifications have been introduced by different authors to improve the mobility and advancement of the flap.

Pontes et al reported "The New Bilaterally Pedicled V-Y Advancement Flap for Face Reconstruction" in 2002. According to this technique the flap is based on two subcutaneous pedicles on both sides of the flap and free at its centre so as to improve the advancement of the flap.<sup>6</sup> We have tried the technique of bipedicle advancement but with no added advancement or superior cosmesis. However the viability of the flap is 100%. Chan ST in 1988 described undermining an oblique pedicle for V-Y flap to enhance its mobility and advancement.<sup>9</sup> The oblique pedicle greatly enhances the advancement of the flap but the cosmesis is poor because the donor area is closed tightly and remains depressed. Pribaz described the "Extended V-Y Flap" in 1992 which included an extension limb to the advancing edge of the flap hinged down as a transposition flap to close the most distal part of the defect.<sup>10</sup> All the above authors have focused on to enhance the mobility and advancement of the flap. We have concentrated on the cosmetic results of the flap. We feel that the conventional vertically pedicled sliding is still versatile and gives excellent aesthetic results which are evident from (Figures). The few non absorbable stitches between the deep surface of the flap and periosteum of the underlying bone is key to the procedure as they keep the flap in the advanced location and prevent traction on the adjacent structures.<sup>8,1</sup> The flap viability was 100% in our study which is comparable to the study of Pontes et al.<sup>6</sup> Kalus and Zamora<sup>7</sup> used this flap in 40 patients. They also used it on the other regions of the body. They found it versatile. The only disadvantage, they found was undesirable buiscuiting or flap odema. In our



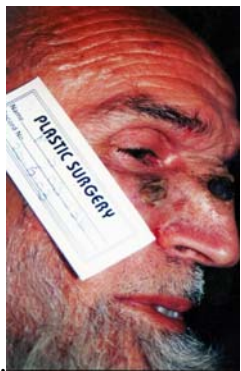
**Figure - 1(A)**

- a. Basal cell carcinoma left infraorbital.
- b. Marking for excision of tumour and outlining of flap.
- c. Cheek defect (3.8cm) after tumour excision.
- d. Sliding island flap raised, advanced to the defect and stitched to the periosteum of the infraorbital bone.

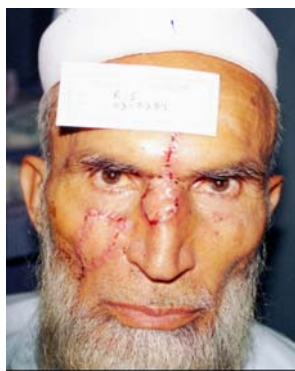

**Figure - 1(B)**

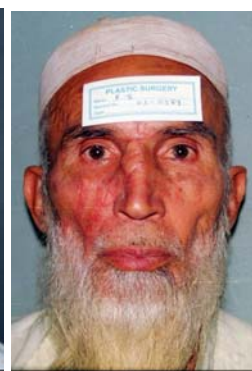- a. Closure of the defect with flap
- b. Postoperative at 02 months follow up
- c. Normal closure of eye without any ectropion
- d. Aesthetic results at 04 months follow up.



**Fig 2(a)**



**Fig 2(b)**



**Fig 2(c)**



**Fig 2(d)**

- a. Basal cell carcinoma right infraorbital- Preoperative
- b. 5<sup>th</sup> Postoperative day after removal of stitches.
- c. One month postoperatively there is minimum scarring.
- d. At 06 months postoperative follow up – completely normal and symmetrical face without any visible scar.

study we have not faced this problem because we keep the pedicle wide. This procedure is simple to perform under local anesthesia in short operating time. If reconstruction is to be done with a regional flap, it has to be done under prolonged general anesthesia for which the old age individuals are poor candidates. Regional flaps give poor colour and texture to the face, excessive bulkiness and donor site morbidity.

## CONCLUSION

This study shows that cosmetic results are good when cheek defect is closed with local flap. Vertically pedicled sliding island flap is a simple and satisfactory alternative for closing relatively larger defects in the malar and infra orbital region of the face in old age individuals.<sup>12</sup> As compare to other methods it is easy to design, reliable and gives excellent aesthetic results in carefully selected patients.<sup>12</sup> The donor area is easily camouflaged by direct closure without any dog ear. Operative time and hospital stay is short as the procedure is performed under local anesthesia as day case.

## REFERENCES

1. Julia K, Padgett MD, John D, Hendrix, Jr, MD. Cutaneous malignancies and their management. *Otolaryngol Clin North Am* 2001;34: 523-53.
2. Inigo F, Jimenez-Murat Y, Rojo P, Ysunza A. Frontotemporal island flap for facial aesthetic subunit reconstruction. *J Craniofac Surg* 1999;10: 330-6.
3. Wayne F, Larrabee Jr. Design of local skin flaps. *Otolaryngol Clin North Am* 1999;23:899-923.
4. Kovcic M. Reconstruction of total lower lip,labial commissure and palatomaxillary defect with composite island cheek flap. *Acta Med Croatica* 2001;55(3):135-9.
5. Pallua N, Magnus Noah E. The tunneled supraclavicular island flap: an optimized technique for head and neck reconstruction. *Plast Reconstr Surg* 2000;105:842-51.
6. Pontes L, Ribeiro M, Vrancks JJ, Guimaraes J. The new bilaterally Pedicled V-Y advancement flap for face reconstruction. *Plast Reconstr Surg* 2002;109:1870-4.
7. Kalus R, Zamora S. Aesthetic consideration in facial reconstructive surgery: the V-Y flap revisited. *Plast Reconstr Surg* 1992;90:275-80.
8. Okazaki M, Haramoto U, Akizuki T, Kurakata M, Ohura N, Ohmori K. Avoiding ectropion by using the Mitek Anchore System for flap fixation to facial bones. *Ann Plast Surg* 1998; 40:169-73.
9. Chan ST. A technique of undermining a V-Y subcutaneous island flap to maximize advancement. *Br J Plast Surg* 1988;41:62-7.
10. Pribaz JJ, Chester CH, Barall DT. The extended V-Y flap. *Plas Reconstr Surg* 1992;90:275.
11. Hudson DA, Quarmby C, Ndob E. A suture suspension technique to prevent ectropion after flap transposition from neck to face. *Plast Reconstr Surg* 2001;108:1692-5
12. Yildirim S, Akoz T, Akan M, Avci G. Nasolabial V-Y Advancement for closure of midface defects. *Dermatol Surg* 2001;27:656-8.

---

### Address for Correspondence:

Dr. Hidayatullah, H.No:160, St-3, J-4, Hayatabad Phase-II Peshawar. Phone: 0300-5942645. Department of Plastic and Reconstructive Surgery PGMI Hayatabad Medical Complex Peshawar.

### Email: