

CASE REPORT

CANCER EN CUIRASSE

Khadimullah Kakakhel, A. Karim Saeed

*Abstract:* Skin metastases in the form of cancer en Cuirasse (scirrhous carcinoma) is an uncommon but typical pattern. The primary site may be known or not yet diagnosed. In this form infiltrated, painful, diffuse plaques are observed. A biopsy is mandatory for diagnosis. In the case where biopsy is confirmative and primary site is not found, examination and relevant investigations should be repeated. In minority of cases skin metastases may be the sole secondaries and excision of these alongwith the primary may give better prognosis. However, excision or radio-therapy may alleviate symptoms.

Case Report

M. R., a 62 years old male from Kohistan (NWFP, Pakistan) presented with severe pain and a lesion on the left side and back of neck of four weeks duration. This lesion and the pain had gradually increased. The pain was boring in character and so severe that it disturbed his sleep. He had smoked 10-20 cigarettes a day for 25 years but had stopped smoking for the last six years. The reason he gave for giving up smoking was the development of a chronic productive cough which had improved since. The patient had no other complaints to suggest disease of gastro-intestinal tract, kidney, prostate, liver or bone. Examination of all these systems, including a rectal examination were normal. He had stayed afebrile through out his illness.

The skin lesion was an infiltrated plaque, erythematous, non-oozing and brown in colour and was slightly tender. No ulcer was seen. It extended from the left ear above to the clavicle below as well as to the left side of back of the neck (Fig. 1). The edges were not sharply demarcated and the lesion was significantly warmer than the normal skin.

Except for an E.S.R. which was raised to 85mm in the first hour all the investigations which included full blood count, urine analysis and chest X-Ray were normal.

A deep biopsy was taken from the site of maximum infiltration. Following the biopsy, the patient was prescribed analgesics (difflusinal 500 mg twice daily) and sedated with Diazepam 10 mg at night. No local medication was prescribed.

The biopsy report confirmed the clinical diagnosis of undifferentiated metastatic malignant tumour of the skin. The pathology report could not point to the site of the primary. The patient was prescribed pentazocine 50 mg four times daily and referred to IRNUM, Peshawar for palliative radiotherapy. The pain which had by now increased and was excruciating was controlled with radiotherapy. Two weeks later the patient developed severe pain in the abdomen. X-Ray chest at this stage revealed the primary in the chest. Features of intestinal obstruction developed which were managed

---

From Ayub Medical College, Abbottabad

KHADIMULLAH KAKAKHEL, MBBS, DDV, FAMS, Dept of Dermatology

A. KARIM SAEED, MBBS, MRCP, Prof of Medicine

conservatively. The patient died within a week time after developing intestinal obstruction.

### Discussion

Metastatic tumours are formed by malignant cells originating from a remote site and frequently another tissue which is spread to the skin by the blood or lymphatic circulation.<sup>1</sup>

The skin is involved by metastases in 2.7% of malignant tumours.<sup>2</sup> The most frequent primary sites are breast, stomach, lung, uterus, large intestine, kidney, prostate, ovary, liver and bone. In men, lung has the primary in about 24% cases of cutaneous metastases.<sup>3,4</sup>

Occasionally the skin lesion may be the first evidence of internal malignancy though usually skin metastases is a late event in the course of internal malignancy and points to a fatal outcome in 3-6 months.<sup>5,6</sup>

Cancer en Cuirasse is a rare but distinctive pattern of metastases in skin. It looks like morphea (localised scleroderma) showing infiltrated, thickened lesion which may be mammilated at places.<sup>7</sup>

Histologically Cancer en Cuirasse, also referred to as scirrhous carcinoma shows fibrosis and only a few tumour cells (Fig. 2). These may be easily overlooked because of their resemblance to fibroblasts. The tumour cells often lie singly, in some areas they lie in small groups or in single-row lines between collagen bundles. This arrangement in single-row-lines, referred to as Indian filing is of particular diagnostic importance.<sup>8</sup> The cells are typical in character having large, pleomorphic, hyperchromatic nuclei.

This case has been reported to remind the readers to examine the skin closely for infiltrated skin lesions or localised plaques and nodules which may be secondary of an internal primary carcinoma. As this may antedate the discovery of a primary, though, investigative search is mandatory. The investigations should be repeated after a period of time, if inconclusive in the first instant.

### REFERENCES

1. Brownstein, M.H. and Helwig, E.B. Patterns of cutaneous metastases. *Arch. Derm.* 1972; 105: 862-866.
2. Gates, O. Cutaneous metastasis of malignant diseases. *Am. J. Cancer* 1937; 30: 718-730.
3. Brownstein, M.H. and Helwig, E.B. Spread of tumours to the skin. *Arch. Dermatol.* 1973; 107: 80-86.
4. Brownstein, M.H. and Helwig, E.B. Metastatic tumours of skin *Cancer.* 1972; 29: 1298-1307.
5. Edelstein, J.M. Pancreatic Carcinoma with usual metastases to the skin and subcutaneous tissue simulating cellulitis. *New Eng. J. Med.* 1950; 242: 779-781.
6. Horiguchi, Y; Takahashi, C. and Immanura, S. Cutaneous metastases from papillary carcinoma of the thyroid gland. *J. Am. Acad. Dermatol.* 1984; 10: 988-992.
7. Auty, R.M. Dermal metastases from a follicular carcinoma of the thyroid. *Arch. Dermatol.* 1977; 113: 675-676.
8. Lever, W.F. and Lever, G.S. *Histopathology of the skin.* Sixth edition, J.B. Lippincott Co. Philadelphia. 1983; 590-595.



CASE REPORT

HOOK WORM INFESTATION IN TEN WEEKS OLD INFANT

Mehr Dil Wazir, S. Humayun Shah, and Wali Mohammad

**Abstract:** Hook worm infestation in early infancy is rarely seen. We report a 26 weeks old infant who presented with severe anaemia and passage of dark colour stool. The patient had a history of diarrhoea and worms. Haemolysis was noticed. The patient was treated with albendazole and mebendazole. Parasites

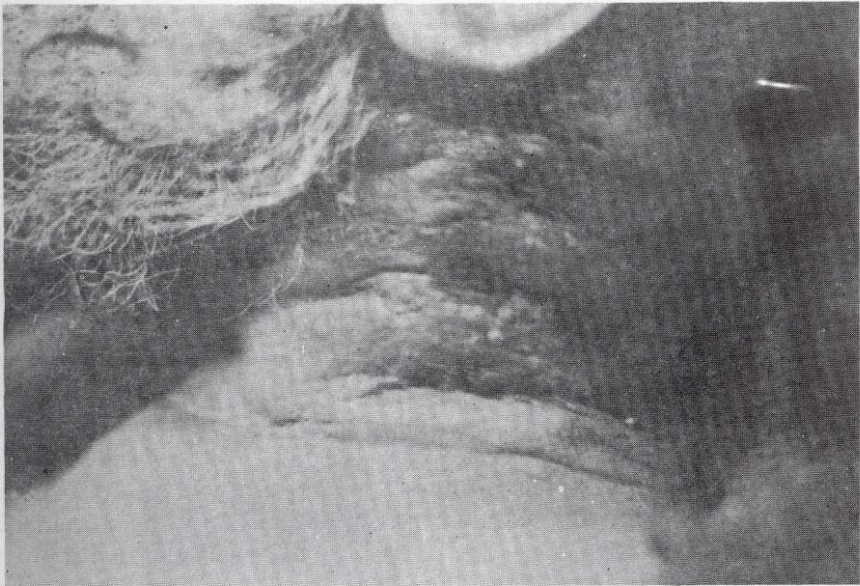


Fig. - 1

One Ankylostoma duodenale worm was found in the stool. The patient was treated with albendazole 15 to 0.28 ml/kg body weight daily for 3 days. The patient presented itself as severely anaemic. Growth retardation and occasionally haemolysis may also be the presenting early symptoms.

Diagnosis depends upon the detection of ova in stool together with a strongly positive faecal occult blood and microcytic and hypochromic anaemia.

Prevention is bound up with effective disposal of faeces and avoiding bare footed walking.

From Ayub Medical College, Abbottabad  
MEHR DIL WAZIR, MBS, DCM, FCSI, Prof of Paediatrics  
S. HUMAYUN SHAH, MBS, DCM, M.Phil, Dept of Pathology  
WALI MOHAMMAD, MBS, Registrar, Dept of Paediatrics

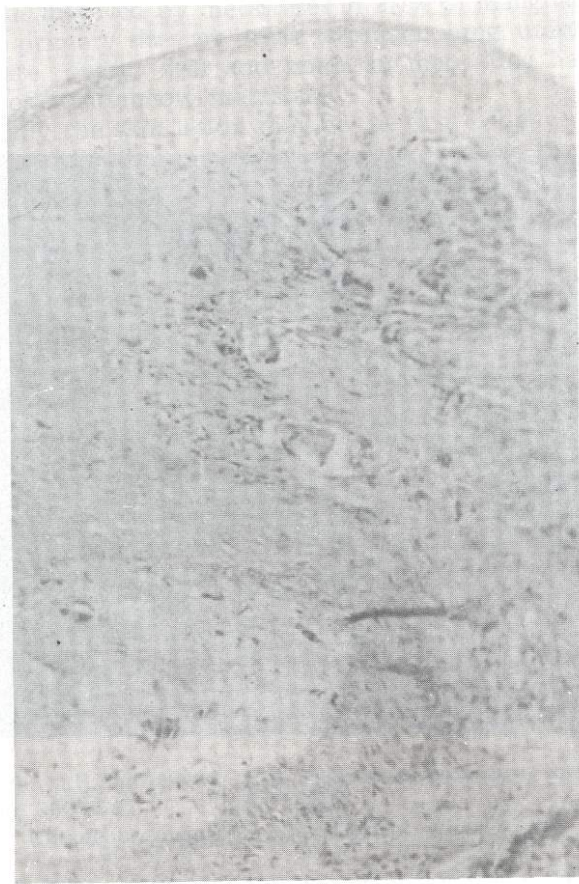


Fig.-2