

ORIGINAL ARTICLE

OUTCOMES FOLLOWING “DOUBLE KNOT” SUSPENSION ARTHROPLASTY FOR BASAL JOINT ARTHRITIS OF THE THUMB

Mustafa Javed, Tarek Nazar, Andrew M Collier

Harrogate District Hospital, Lancaster Park Road, Harrogate, North Yorkshire, HG2 7SX-United Kingdom

Background: Various surgical options used in the treatment of osteoarthritis of the basal joint of the thumb that are refractory to non-surgical management. This study was conducted to provide short term functional outcomes using the mentioned technique in treating basal joint arthritis of the thumb. **Methods:** We treated basal joint arthritis of the thumb by trapeziectomy and volar oblique ligament reconstruction using flexor carpi radialis tendon and “suspension” interposition arthroplasty using the entire tendon split along its length and tied as a double knot at the base of the thumb metacarpal. Through a questionnaire based survey, we reviewed 24 thumbs in 24 patients with basal joint arthritis of the thumb who were followed up with the hand therapist. Postal questionnaires were sent to these patients to record DASH scores and satisfaction. **Results:** The mean time from surgery to discharge by the hand therapist following rehabilitation was 10 weeks. The DASH score averaged 25 points at 12 weeks postoperatively. There was statistical significance (p -value=0.0001) between the DASH score compared with time spent with the hand therapist. The postoperative net difference in grip strength and pinch grip compared with non-operated had was 9 kg and 3 kg respectively and the net difference in web span was 2 cm. **Conclusion:** We suggest this technique of “suspension” arthroplasty is a safe and effective method in treating basal joint arthritis of the thumb with good short-term functional outcomes and minimal complications.

Keywords: Basal Joint Arthritis, Trapeziectomy, Volar Oblique Ligament Reconstruction, “Suspension” Interposition Arthroplasty, DASH

J Ayub Med Coll Abbottabad 2015;27(1):3-7

INTRODUCTION

Various surgical options used in the treatment of osteoarthritis of the basal joint of the thumb that are refractory to non-surgical management include arthrodesis¹⁻⁵, simple trapeziectomy⁶, trapeziectomy with ligament reconstruction and interposition arthroplasty⁷, silicone-rubber interposition arthroplasty⁸, and total joint replacement⁹ showing various reported outcomes. There is controversy on these procedures as to which provides the best outcome.^{6,10} Trapeziectomy with ligament reconstruction and interposition arthroplasty has been found to be effective in restoring a pain-free and functional thumb.¹¹

We prefer the surgical technique of using the flexor carpi radialis (FCR) tendon to reconstruct the volar oblique ligament (VOL) after trapeziectomy. There are perceived advantages with this technique such as an improvement in grip and pinch strength from baseline, ease of performing activities of daily living and a subjective decrease in pain with reports of no pain or pain with exertional activities only.¹²⁻¹⁴

We modified the technique by simple trapeziectomy and recruiting the FCR tendon in its entirety detached at the musculo-tendinous junction. It is split into two longitudinal halves and tied through the base of the thumb metacarpal in a double knot. This serves a two-fold purpose. Firstly, it reconstructs the VOL or the beak ligament. Secondly, it “suspends” the

basal joint to restore length, which is further augmented by “interposition” of the remainder plicate ligament into the space previously occupied by the trapezium.

The purpose of this study was to provide short term functional outcomes using the mentioned technique in treating basal joint arthritis of the thumb.

MATERIAL AND METHODS

This cross-sectional survey was conducted on a series of patients treated with trapeziectomy and VOL ligament reconstruction with FCR graft tendon. Postal questionnaires were sent to all patients after seeking approval from our local clinical effectiveness committee.

We received twenty-four completely filled questionnaires, which were included in the study. We were not at liberty to enquire from the patients who did not return the forms completely filled or did not return them at all as it was presumed that these particular patients did not consent to share their experience after surgery.

Twenty-four patients were operated using the technique. These patients had an unsuccessful trial of non-operative treatment that included non-steroidal anti-inflammatory drugs, a steroid injection for both diagnostic and therapeutic purposes, and physiotherapy. The study was conducted at our institution between 2007 and 2011.

The diagnosis of basal joint arthritis was confirmed both with clinical and radiological findings. Clinically, there was persistence of pain and tenderness over the base of the metacarpal of the thumb that worsened by axial loading of the thumb. The arthritis was classified according to the Eaton and Littler staging¹² showing joint space narrowing, sclerosis and cyst formation. All 24 patients were classified as stage 4 (advanced disease) for basal joint arthritis. Pre-operative stiffness at the metacarpophalangeal joints and interphalangeal joints was noted for comparison postoperatively.

The study subjects were 18 women and 6 men. Their mean age was 67 years (range 57–85 years) at the time of the procedure. These patients were asked about their hobbies and were counselled for loss of FCR function mostly noticed in specific movements such as playing the violin or the cello. The mean follow-up with the hand therapist was 10.41 weeks (range 9–17 weeks) post-operatively. The patients were identified on our hospital database and were sent the Disabilities of the Arm, Shoulder and Hand (DASH)¹³ questionnaire via post after completion of treatment (12 weeks post-operatively) and approval from our clinical effectiveness committee. The outpatient hand therapy records for these patients were also studied.

The first author performed all the procedures. The operations were performed under a general anaesthetic. Sterile Esmarch's bandage was applied for exsanguination prior to inflation of an upper arm tourniquet. A lazy "S" incision centred over the base of the thumb was made from the dorsal distally to volar proximally. The superficial branches of the radial nerve and the deep branch of the radial artery were identified and protected. The plane between the abductor pollicis longus and extensor pollicis brevis was developed. An inverted 'T' incision to the capsule allowed exposure to the trapezium which was completely excised by longitudinal multiple segmentations of the bone using small sized osteotome.

A tunnel was burred through the base of the thumb metacarpal in the dorsal midline to the insertion of the VOL wide enough to pass one limb of the FCR tendon through it (Figure-1). Two transverse incisions were made proximal to the distal palmar crease and one transverse incision over the mid-forearm to harvest the FCR tendon graft. The freed FCR tendon is split longitudinally in two limbs one of which is passed through the tunnel at the base of the thumb metacarpal (Figure-2). Two limbs of the FCR are tied into double knots and then secured with a stitch of monofilament (PDS) suture (Figure-3). The suture is then run through the remainder of the tendon in a running fashion and then weaved into tendon mass acting as a spacer in the space created by "suspension" arthroplasty following VOL reconstruction by double knot tying of the two

limbs of the FCR tendon (Figure-4). This tendon mass is secured in the trapezium fossa with the deep capsular suture and with capsular closure. No Kirschner wires are used to add temporary stability to the basal joint. The incision is closed with absorbable 3-0 vicryl rapide suture and steri-strips.

All patients followed a standard post-operative rehabilitation programme. The thumb was initially immobilised in a back slab for 8 days at which stage the patients were reviewed in clinic for a wound check and then a thermoplastic splint was applied for six weeks with thumb in abduction and extension. The patients were advised rest, maintenance of hygiene and being vigilant for any signs of infection during their time in the thermoplastic splint. The hand therapist commenced early gentle thumb and wrist mobilisation after removal of the splint for the first two weeks. Around four weeks after removal of splint, active thumb and wrist joint immobilisation was started. Strengthening exercises were started at six weeks after removal of the splint.

The hand therapist followed the patients at two, four, six and twelve weeks post-operatively. The hand therapist recorded the outcome assessment at each visit and the measurements at the final visit (at 12 weeks post-operatively) were analysed for the study.

Kapandji Scores¹⁴ were used to assess the ability of the thumb to touch the palmar crease of the little finger with the thumb tip. Power grip, pinch grip and lateral key grip was measured with a dynamometer and compared to the contralateral hand. The first web space was measured from the tip of the thumb to the tip of the index finger. The outcome assessment was compared with the non-operated hand. The non-operated hand was also assessed on clinical and radiological grounds for basal joint arthritis.

Complications were recorded. A statistical difference was calculated using the Fisher Exact test. A *p*-value of less than 0.05 was taken as significant. The Pearson product correlation co-efficient was used to describe the strength of relationships between variables.

RESULTS

The average post-operative DASH scores at 12 weeks were 25 points (range 0.8–54.3). The time taken by the hand therapist to discharge patient was 10.41 weeks (range 9–17 weeks). There was statistically significant results when comparing DASH scores with time spent with the hand therapist (*p*-value=0.0001) with a correlation coefficient of -0.26 which suggests that the longer the hand therapist reviews the patient, the better the DASH scores.

There was also net loss of 9.04 degrees in metacarpophalangeal joint flexion (*p*-value=0.0001) and 14.45 degrees interphalangeal joint flexion (*p*-value=0.047) following the suspension arthroplasty compared to the non-operated hand.

The mean Kapandji score was 7.87. The net grip strength, pinch grip and net web space span improved as compared to the unaffected hand averaged at 8.65 kilograms (kg), 3.125 kg and 2 centimetres (cm) respectively (Table-1). All patients reported to have returned to their activities of daily living at final follow up. Overall complication rate was 4.16% (1/24). One patient had superficial infection and had good response to oral antibiotics. There was no complex regional pain syndrome, neurovascular or tendon injury noted.

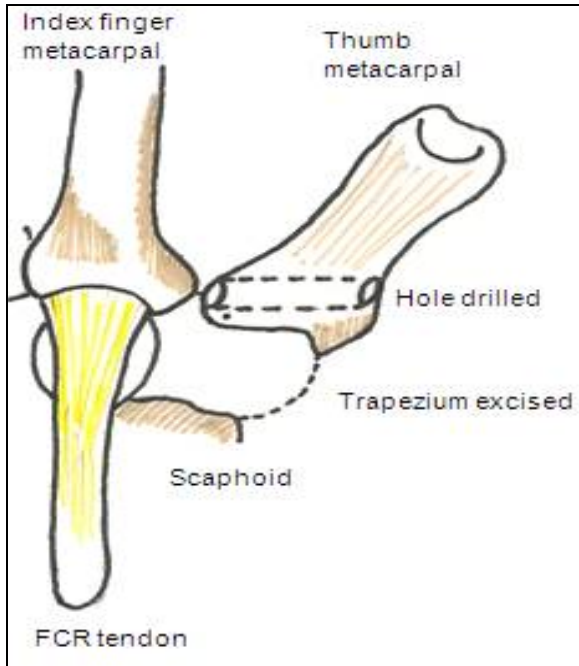


Figure-1: Excision of trapezium and Drilling of hole in the base of thumb metacarpal.

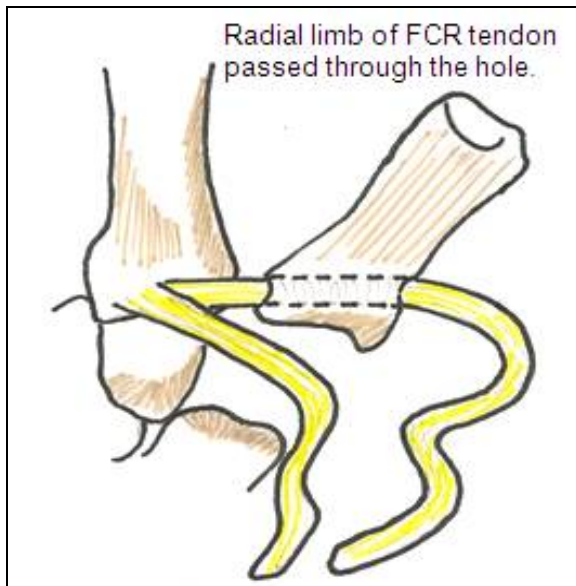


Figure-2: Passing of Radial Limb of FCR tendon through the hole

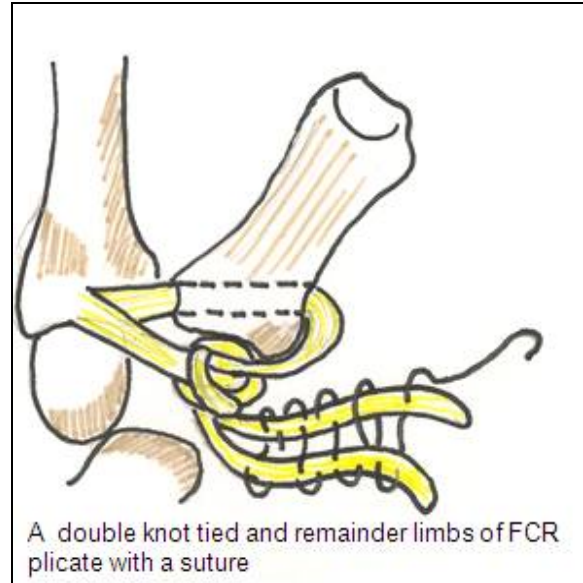


Figure-3: The “double knot”

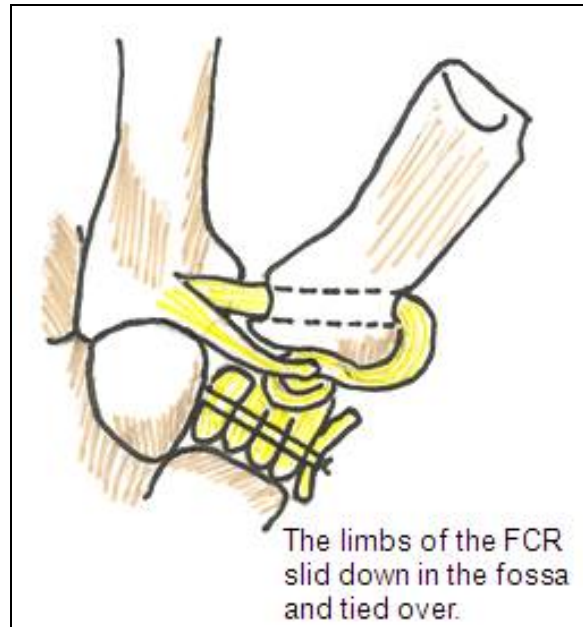


Figure-4: The FCR tendon positioned in the trapezium fossa.

Table-1: Functional Outcomes compared to non-operated hand

| | | |
|---------------------|----------------|---------------------------|
| Mean Kapandji score | 7.87 | |
| Grip strength | +8.65 kg | |
| Pinch grip | +3.125 kg | |
| Web space span | +2 cm | |
| MCPJ flexion | -9.04 degrees | <i>p</i> -value=0.000132* |
| IPJ flexion | -14.45 degrees | <i>p</i> -value=0.047405* |

DISCUSSION

Arthritis of the basal joint of thumb causes symptoms including pain, stiffness, and subluxation causing pinch and grasp impairment.^{15,16} A trial of non-operative treatment.^{16,17} is usually considered initially

which include use of anti-inflammatory drugs, thumb spica splinting and intra-articular injection of steroids. More recently hyaluronic injections¹⁸ have been used to try to avoid or delay operative treatment.

Patients who are refractory to non-operative measures and continue to have pain, deformity and weakness that interfere with daily function should be offered surgical intervention. Reconstruction of the VOL and tendon interposition using the FCR tendon was first described by Burton.¹⁹ It was an effective procedure in improving the stability of basal joint by reconstruction of the VOL, which functions as a restraint against dorsal angulation.²⁰ In addition, the use of suspension arthroplasty can prevent proximal metacarpal migration and facilitate early recovery of thumb strength.¹⁹ De Smet *et al*²¹ reported that collapse of the trapezial height following ligament reconstruction was up to 50% and more so in isolated trapeziectomy without ligament reconstruction.

Our modified technique includes excision of the entire trapezium to reduce pain at the articulation with the first metacarpal. We used the entire length of the FCR tendon and tied a "double" knot through the base of the first metacarpal in order to suspend it at the intended position hence restoring height and preventing axial shortening. The remaining tendon graft was used as soft tissue interposition as the length was sufficient to fill the void area to help maintain trapezial fossa height and theoretically avoid instability and proximal metacarpal migration.²² Werner *et al*²³ tested fresh frozen cadaver wrists using a wrist joint motion stimulator and subjected forces to the FCR tendon. They noted that removal of the entire FCR should, despite excellent clinical results, lead to wrist weakness. As the FCR is least affected during dart throwing motion during which the fewest symptoms should be seen. The study predicted that patients undergoing harvest of all or portion of the FCR tendon may experience decreasing wrist strength with wrist motion as the FCR tendon normally applies force during wrist motion. The motion least likely to be affected is the dart throwing motion when the force on the remaining FCR is minimised.

One possible reason for good clinical results following FCR tendon harvest graft has been suggested by Beall *et al*²⁴ based on an MRI study, they reported that in 14 patients, in which the entire FCR was used for LRTI, 79% had partial regeneration and 14% had complete regeneration of the FCR.

With our technique, we avoid the use of a Kirschner wire for temporary stabilisation of the ligament reconstruction, which has an associated morbidity of soft tissue complications.²⁵ In a recent

randomised prospective study by Salem¹⁷ basal joint arthritis of the thumb was either treated with simple trapeziectomy alone or trapeziectomy and ligament reconstruction and tendon interposition with Kirschner wire stabilisation temporarily; the DASH scores were 31 and 30 points while the pinch grip was measured at 3.7 kg and 4.1 kg respectively. Our results are comparable to these with improvement in DASH scores.

It was noted in our study that there is loss of MCP and IP joint flexion in the operated hand and this we suspect is due to fibrosis post-operatively in the extensor tendons of the thumb. A further contributory factor is the pre-operative stiffness, which is not always completely correctable. This has however not impeded postoperative recovery as all patients returned to their activities of daily living.

It may be postulated that the reduction in range of movements could be due to long period of postoperative immobilisation. Postoperative rehabilitation and splinting protocols have varied widely between institutions. In fact, no studies have been published looking specifically at these protocols. Bodin *et al*²⁶ alluded to therapy after eight weeks of casting but no specific protocol is defined. A single blinded randomised control trial under way to compare early versus delayed motion after ligament reconstruction tendon interposition for basal arthritis of the thumb.²⁷ We follow a more conservative rehabilitation protocol as discussed.

The FCR taken in its entirety may raise the question about reduction in palmar flexion and radial deviation but in our post-operative assessment, patients have had improved grip strength as this comes from wrist extension. There is an argument to detach a single limb from the FCR in professional string instrument players such as the violin or cello. During our pre-operative consultations with patients, we found that the patients preferred pain relief to limited functional loss. Since CMC joint arthritis is the disease of individuals in later decades of life with a lower demand to activities, we feel the benefits discussed in this study of using the FCR in its entirety will outweigh compromise in movements in certain groups of patients.

There are several strengths to be noted about this study. We introduce a technique of interposition arthroplasty for basal joint arthritis which has not been previously reported. The study also provides a comprehensive assessment of functional outcomes. We suggest that with our technique, long term follow-up is not required as good DASH scores and ranges of movements of the thumb are statistically significant at ten weeks when the patient is discharged from the hand therapist's care. To our

knowledge and our search of literature, such comparisons have previously not been reported.

CONCLUSION

We conclude that “double knot” suspension arthroplasty with VOL reconstruction using FCR tendon graft and interposition arthroplasty is an effective method of surgically treating basal arthritis of the thumb with good short-term functional results and presents with minimal complications.

REFERENCES

- Burton RI. Basal joint arthritis. Fusion, implant, or soft tissue reconstruction? *Orthop Clin North Am* 1986;17(3):493–503.
- Burton RI, Margles SW, Lunseth PA. Small-joint arthrodesis in the hand. *J Hand Surg Am* 1986;11(5):678–82.
- De Smet L, Vaes F, Van Den Broecke J. Arthrodesis of the trapeziometacarpal joint for basal joint osteoarthritis of the thumb: the importance of obtaining osseous union. *Chir Main* 2005;24(5):222–4.
- Lutonsky M, Pellar D. Arthrodesis of the carpometacarpal joint of the thumb. *Acta Chir Orthop Traumatol Cech* 2006;73(5):345–9.
- Pustisek B. Arthrodesis of the basal joint of the big toe. *Z Orthop Ihre Grenzgeb* 1973;111(4):465–6.
- Li YK, White C, Ignacy TA, Thoma A. Comparison of trapeziectomy and trapeziectomy with ligament reconstruction and tendon interposition: a systematic literature review. *Plast Reconstr Surg* 2011;128(1):199–207.
- Lins RE, Gelberman RH, McKeown L, Katz JN, Kadiyala RK. Basal joint arthritis: trapeziectomy with ligament reconstruction and tendon interposition arthroplasty. *J Hand Surg Am* 1996;21(2):202–9.
- Minami A, Iwasaki N, Kutsumi K, Suenaga N, Yasuda K. A long-term follow-up of silicone-rubber interposition arthroplasty for osteoarthritis of the thumb carpometacarpal joint. *Hand Surg* 2005;10(1):77–82.
- Badia A, Sambandam SN. Total joint arthroplasty in the treatment of advanced stages of thumb carpometacarpal joint osteoarthritis. *J Hand Surg Am* 2006;31(10):1605–14.
- De Smet L, Van Meir N, Verhoeven N, Degreef I. Is there still a place for arthrodesis in the surgical treatment of basal joint osteoarthritis of the thumb? *Acta Orthop Belg* 2010;76(6):719–24.
- Ghavami A, Oishi SN. Thumb trapeziometacarpal arthritis: treatment with ligament reconstruction tendon interposition arthroplasty. *Plast Reconstr Surg* 2006;117(6):116e–128e.
- Burton RI, Pellegrini VD, Jr. Surgical management of basal joint arthritis of the thumb. Part II. Ligament reconstruction with tendon interposition arthroplasty. *J Hand Surg Am* 1986;11(3):324–32.
- Nylen S, Johnson A, Rosenquist AM. Trapeziectomy and ligament reconstruction for osteoarthritis of the base of the thumb. A prospective study of 100 operations. *J Hand Surg Br* 1993;18(5):616–9.
- Tomaino MM, Pellegrini VD, Jr, Burton RI. Arthroplasty of the basal joint of the thumb. Long-term follow-up after ligament reconstruction with tendon interposition. *J Bone Joint Surg Am* 1995;77(3):346–55.
- Avisar E, Wasrbout Z, Lin E, Agashi M. The thumb in agony--osteoarthritis of the thumb. *Harefuah* 2011;150(10):797–800.
- Ho PK, Jacobs JL, Clark GL. Trapezium implant arthroplasty: evaluation of a semiconstrained implant. *J Hand Surg Am* 1985;10(5):654–60.
- Salem H, Davis TR. Six year outcome excision of the trapezium for trapeziometacarpal joint osteoarthritis: is it improved by ligament reconstruction and temporary Kirschner wire insertion? *J Hand Surg Eur Vol* 2012;37(3):211–9.
- Heyworth BE, Lee JH, Kim PD, Lipton CB, Strauch RJ, Rosenwasser MP. Hylan versus corticosteroid versus placebo for treatment of basal joint arthritis: a prospective, randomized, double-blinded clinical trial. *J Hand Surg Am* 2008;33(1):40–8.
- Burton RI, Pellegrini VD, Jr. Surgical management of basal joint arthritis of the thumb. Part II. Ligament reconstruction with tendon interposition arthroplasty. *J Hand Surg Am* 1986;11(3):324–32.
- Wong TC, Ip FK. A modified technique of interpositional arthroplasty in treating the Basal joint arthritis of the thumb in a Chinese population. *Hand Surg* 2009;14(2-3):83–7.
- De Smet L, Sioen W, Spaepen D, van Ransbeeck H. Treatment of basal joint arthritis of the thumb: trapeziectomy with or without tendon interposition/ligament reconstruction. *Hand Surg* 2004;9(1):5–9.
- Yang SS, Weiland AJ. First metacarpal subsidence during pinch after ligament reconstruction and tendon interposition basal joint arthroplasty of the thumb. *J Hand Surg Am* 1998;23(5):879–83.
- Werner FW, Short WH, Palmer AK, Sutton LG. Wrist tendon forces during various dynamic wrist motions. *J Hand Surg Am* 2010;35(4):628–32.
- Beall DP, Ritchie ER, Campbell SE, Tran HN, Ingari JV, Sanders TG, *et al.* Magnetic resonance imaging appearance of the flexor carpi radialis tendon after harvest in ligamentous reconstruction tendon interposition arthroplasty. *Skeletal Radiol* 2006;35(3):144–8.
- Koh WI, Lim BH. Soft Tissue Complications Following Kirschner Wire Fixation for Fusion of Basal Joint Arthritis. *Hand Surg* 1999;4(2):197–202.
- Bodin ND, Spangler R, Thoder JJ. Interposition arthroplasty options for carpometacarpal arthritis of the thumb. *Hand Clin* 2010;26(3):339–50.
- University U. Postoperative Rehabilitation Following Trapeziectomy and Ligament Reconstruction Tendon Interposition: a Prospective, Randomized Multi-center Study. November 5, 2012; Available at: <http://clinicaltrials.gov/show/NCT01425034>, August 22, 2011.

Address for Correspondence:

Mr Mustafa Javed, 33, Harewood Crest, Brough, HU15 1QD-UK.

Ph: +44 7760236518

Email: mustafajaved@hotmail.com