

ORIGINAL ARTICLE

EARLY EXPERIENCE OF ENDOVASCULAR TREATMENT OF PERIPHERAL VASCULAR DISEASE

Tariq Ashraf, Kamal Yousuf, Muhammad Tariq Karim

Department of Cardiology, National Institute of Cardiovascular Diseases, Karachi-Pakistan

Background: Atherosclerotic peripheral arterial disease (PAD) is prevalent affecting up to 16% of the population aged 55 years or older. Endovascular intervention for the treatment of limb ischemia has become the first line therapy but in Pakistan it is in embryonic stage due to dearth of trained persons and dedicated centres. This study was conducted to evaluate procedural success and early outcome of endovascular treatment of peripheral vascular disease. **Methods:** A prospective single arm multicentre study was conducted at the National Institute of Cardiovascular Disease and National Medical Centre, Karachi, Pakistan from January 2013 to June 2014. A total of 25 patients were enrolled in the study that underwent endovascular treatment. Out of 25 patients 23 (92%) had critical limb ischemia (CLI) as per TASC II classification (A to D) and 2 (8%) had carotid lesion with history of TIA. Patients of acute limb ischemia and stroke were excluded. Ankle brachial index (ABI) was classified as normal (0.9–1.3), mild (0.7–0.9), moderate (0.4–0.69), severe (<0.4). Outcome was taken as immediate success and symptoms, amputation of limb among CLI patients and incidence of stroke in patients with carotid artery lesion at end of six months. **Results:** Among aortoiliac, femoropopliteal and tibioperoneal lesions, tibioperoneal lesions at six months were found to be more symptomatic 6 (86%) and amputation 4 (57%). Two carotid lesions at follow up were asymptomatic without stroke. **Conclusion:** Endovascular treatment of peripheral vascular lesions, i.e., aortoiliac, femoropopliteal tibioperoneal and carotid lesions were satisfactory in immediate outcome. Tibioperoneal lesions were more symptomatic and limb amputation at six months.

Keywords: Chronic Limb Ischemia (CLI), Endovascular Treatment, Procedural Outcomes

J Ayub Med Coll Abbottabad 2015;27(1):93–5

INTRODUCTION

Atherosclerotic peripheral arterial disease (PAD) is prevalent affecting up to 16% of the population aged 55 years or older and an estimated 27 million Europeans and North Americans.¹ In high risk populations, the prevalence of PAD may be as high as 20–30%.² There is a widespread belief amongst the medical professionals that PAD is a disease of the west and is infrequent in Pakistan. The prevalence of peripheral vascular disease is 5.5% among type-2 diabetes based on absence of dorsalis pedis or posterior tibial pulses.³

Patients with peripheral vascular disease usually presents as intermittent claudication or critical limb ischemia (CLI).⁴⁻⁵ The management of peripheral arterial disease is focused in managing cardiovascular risk factors, i.e., diabetes mellitus, smoking, hypertension, dyslipidaemia, and severity of claudication either by pharmacotherapy and supervised walking or by endovascular or surgical therapy.⁶ Endovascular intervention for the treatment of limb ischemia has become the first line therapy in many centers.⁷⁻⁹ Vascular surgery is in its embryonic stage in Pakistan and there is dearth of trained persons and dedicated centers.¹⁰ We present early experience of 25 cases of peripheral vascular interventions and there outcomes in six months as symptomatic/asymptomatic and amputation of limb.

MATERIAL AND METHODS

This case series was carried out National Institute of Cardiovascular Disease and National Medical Centre, Karachi, Pakistan from January 2013 to June 2014. Patients with critical limb ischemia (CLI) as per TASC II classification (A to D) and carotid lesion with history of TIA referred by vascular surgeon for endovascular treatments were included in the study. Patients with acute limb ischemia and stroke were excluded. Ankle brachial index (ABI) was measured and labelled as per American diabetic association, (ABI 0.9–1.3=Normal, 0.7–0.9=Mild, 0.4–0.69=Moderate and ABI <0.4=Severe). Vascular lesions of lower limb were classified according to TASC classification as described by Inter-society consensus for the management of peripheral arterial and carotid disease. CT-angiography was done prior to endovascular peripheral and carotid interventions in all cases. Stents (Balloon mounted and self-expanding), balloons, wires were used from Boston scientific. Lesions of both peripheral and carotid were accessed from femoral artery. All cases below the knee were accessed ipsilateral antegrade while few cases of superficial femoral artery (SFA) lesions were managed with crossover technique. All common iliac lesions were stented with retrograde access. Patients were given Clopidogrel for one month and aspirin and statins lifetime. Optimal control of hypertension and diabetes was advised. Post procedure they were referred for

rehabilitation in a physiotherapy centre. Statistical analysis was done using SPSS version 21. Data was described cross-tabulation was done to see the effect of lesions on the outcome at 6th month. Chi-square test was applied and *p*-value ≤0.05 was taken as significant.

RESULTS

Baseline characteristics of the patients are shown in Table-1. Procedural success is shown in Figure-1. On cross tabulation there was significant difference observed in outcomes at six months between femoropopliteal, aortoiliac and tibioperoneal lesions (*p*-value 0.024) as shown in table-2. The maximum numbers of amputations 4 (57.1%) were observed in patients with tibioperoneal lesions. Two patients with carotid lesions did not develop stroke till the end of 6th month. (Table-2)

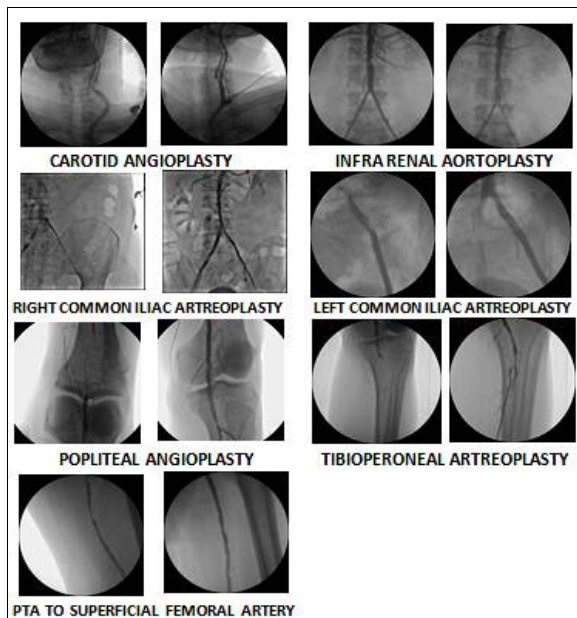


Figure-1: Endovascular Percutaneous Transluminal Angioplasty (PTA)

Table-1: Baseline Characteristics of Patients with Peripheral Vascular Disease (n=25)

Age, years, mean ±SD	58.32±6.60	
	N	%
Gender		
Male	19	76
Female	6	24
Risk Factors		
Diabetes Mellitus	12	48
Hypertension	23	92
Smokers	18	72
Hyperlipidemia	22	88
Pre ABI (Moderate)	23	92
Peripheral Vascular Lesion		
Carotid	2	8
Aortoiliac	7	28
Femoropopliteal	9	36
Tibioperoneal	7	28
Trans-Atlantic Inter-Society Consensus (n=13)		
A	8	32
B	4	16
C	1	4

Table-2: Outcome by type of lesion (n=25)

	Femoropopliteal	Aortoiliac	Tibioperoneal	<i>p</i>
Symptomatic	3 (33.3%)	2 (28.6%)	2 (28.6%)	0.024
Asymptomatic	5 (55.5%)	5 (71.4%)	1 (14.2%)	
Amputation	1 (11.1%)	0 (0%)	4 (57.1%)	
Two patients with carotid lesions did not develop stroke at the end of 6 months				

DISCUSSION

Percutaneous transluminal angioplasty (PTA), use of catheter to re-canalize and dilate occluded arteries was first described in the 1960s by Charles Dotter. Balloon catheter to perform PTA were first used by Andreas Gruentzig in the early 1990s.¹¹ The TASC working group published comprehensive review on management of PAD with guidelines on iliac disease.¹² The guidelines were updated with new TASC II classification for aortoiliac and common femoral arterial disease.¹¹ For simple lesions (TASCA-B), the endovascular treatment is recommended. Recent series even suggest to attempt for even complex cases (TASC C-D), first percutaneously and then in case of failure to surgery.^{13,14} The technical success rate up to 100% and 1 year primary patency rate >85% have been reported.¹⁵ The results of our aortic-iliac lesions are almost the same as of large series. Only one patient with femoropopliteal lesion underwent amputation in 6 months follow-up. This patient had a TASSC-C lesion. Only balloon angioplasty was done in all of the cases without putting a stent. Femoropopliteal disease continues to present endovascular treatment challenges. Balloon angioplasty (BA) result leads to reasonable patency in some lesions.¹⁵ Stents provide solution in case of dissection or suboptimal results. The problem of re-stenosis is still the issue.¹⁶ The issue of re-stenosis may ultimately influence use of drug eluting nitinol stents. There is a dramatic shift in the management of peripheral vascular disease in the last decade.¹⁷ This analysis has demonstrated tibioperoneal angioplasty which is associated with increased rate of readmission and needs for re-intervention within 30 days.¹⁸ We have also demonstrated that overall, almost one quarter of patients treated with tibioperoneal PTA succumbed to amputation and recurrence of symptoms after the initial procedure within 6 months, perhaps representing the sickest cohort of all corners seen in the study. Kudo *et al*,¹⁹ have shown infrapopliteal angioplasty as a reasonable primary treatment for CLI. They concluded that although re-stenosis, re-intervention or amputation are high after tibial angioplasty for CLI, excellent limb salvage rates may be obtained with careful follow up and re-intervention when necessary. These are the patients who are also unsuitable for surgical bypass.

Overall the data for carotid stenting is encouraging. Over the last decade carotid stenting have shown improvements in terms of 30 day mortality and stroke rate.²⁰ Though the number of patients is small in our study, the outcome regarding stroke was uneventful

in six months. Last studies performed over the past decade have shown that carotid artery stenting (CAS), when performed by skilled operators can provide safe and durable options for revascularization.²¹

Health economics also plays a pivotal role in endovascular management of peripheral vascular disease. Studies have published on the cost of treating CLI.²²⁻²⁴ Large number of patients were offered endovascular treatment in the two year period. Most of the patients did not appear because of cost issues. The cost of PTA extends from Pakistan Rupees (Rs.) 160,000.00 to Rs. 300,000.00 depending upon if simple balloon angioplasty is done or stent is used, which is even less as compared to cost of PTA in USA, i.e., 10,000 US \$ (20,000 US \$, if the procedure fails initially or later). The limitation of our study was the less numbers of patients due to poor referral and high cost of the procedure in a private and government hospital set up. Co-existing renal, coronary artery, and carotid artery disease with peripheral vascular disease needs to be worked up. Moreover awareness of general public and doctors for peripheral vascular disease and its management needs consideration. In conclusion the important feature of critical limb ischemia is dismal prognosis for limb outcomes because of generalized atherosclerosis. Endovascular revascularization may reduce pain and improve quality of life. Aortoiliac and Femoropopliteal lesions have shown to have remarkable outcomes as compared to tibioperoneal lesions which at the end of six months ended up with symptoms and amputation.

REFERENCES

- Belch JJ, Topol EJ, Agnelli G, Bertrand M, Califf RM, Clement DL, *et al.* Critical issues in peripheral arterial disease detection and management: a call to action. *Arch Intern Med* 2003;163(8):884-92.
- Hirsch AT, Criqui MH, Treat-Jackson D, Regensteiner JG, Creager MA, Olin JW, *et al.* Peripheral arterial disease detection, awareness and treatment in Primary care. *JAMA* 2001;286(11):1317-24.
- Basit A, Hydrie MZ, Hakeam R, Ahmedani MY, Masood Q. Frequency of chronic complications of Type II diabetes. *J Coll. Physician Surg Pak* 2004;14(2)79-83.
- Donmedly R. Evidence based symptom relief of intermittent claudication. Efficacy and safety of cilostazol. *Diabetes Obes Metab* 2002;4:S20-5.
- American Diabetic Association. Peripheral arterial disease in people with diabetes. *Diabetes Care* 2003;26(12):3333-41.
- Gey DC, Lesho EP, Manngold J. Management of peripheral arterial disease. *Am Fam Physician* 2004;69(3):525-32.
- DeRubertis BG, Faries PL, McKinsey JF, Chaer RA, Pierce M, Karwowski J, Weinberg A, *et al.* Shifting paradigms in the treatment of lower extremity vascular disease: A report of 1000 percutaneous interventions. *Ann Surg* 2007;246(3):415-22.
- Sadak M, Ellozy SH, Turnbull IC, Lookstein RA, Marin ML, Faries PL, *et al.* Improved outcomes are associated with multilevel endovascular interventions involving the tibial vessels compared with isolated tibial interventions. *J Vas Surg* 2009;49(3):638-43.
- Black JH 3rd, La Muraglia GM, Kwolek CJ, Brewster DC, Watkins MT, Cambria RP, *et al.* Contemporary results of angioplasty based infringuinal percutaneous interventions. *J Vasc Surg* 2005;42(5):932-9.
- Rehman ZU, Sophie Z. Vascular surgery in Pakistan: Critical issues. *J Coll Physician Surg Pak* 2014;24(6):381-2.
- Gruntzig A. Transluminal dilatation of coronary artery stenosis. *Lancet* 1978;1(8058):263.
- Norgen L, Hiatt WR, Dormandy JA, Nehler MR, Harris KA, Fowkes FG, *et al.* Inter society consensus for the management of peripheral arterial disease(TASCII). *J Vasc Surg* 2007;45 Suppl S:55-67.
- Sixt S, Alawied AK, Rastan A, Schwarzwald U, Kleim M, Noory E, *et al.* Acute & long term outcome of endovascular therapy for aortoiliac occlusive lesions stratified according to the TASC classification: A single centre experience. *J Endovasc Ther* 2008;15(4):408-16.
- Levilla CD, Kashyap VS, Clain DG, Bena JF, Lyden SP, Greenbag RK, *et al.* Endovascular management of iliac artery occlusions: Extending treatment to Transatlantic Intersociety Consensus Class C&D patients. *J Vasc surg* 2006;43(1):32-9.
- Davies MG, Saad WE, Peden EK, Mohiuddi IT, Naoum JJ, Lumsden AB. Percutaneous superficial femoral artery interventions for claudication-does runoff matter? *Ann Vasc Surg* 2008;22(6):790-8.
- Dake MD, Ansel GM, Jaff MR, okai T, Saxon RR, Smouse HB, *et al.* Paclitaxel eluting stents show superiority to balloon angioplasty & bare metal stents in femoropopliteal disease: Twelve month Zilver PTX randomized study results. *Circ Cardiovasc Interv* 2011;4(5):495-504 .
- Goodney PP, Beck AW, Nagle J, Welch HG, Zwolak RM. National trends in lower extremity by pass surgery, endovascular interventions & major amputations. *J Vasc Surg* 2009;50(1):54-60.
- Vogel TR, Dombrovskiy VY, Carson JL, Graham AM. In-hospital and 30-day outcomes after tibioperoneal interventions in the US Medicare population with critical limb ischemia. *J Vasc Surg* 2011;54(1):109-15.
- Kudo T, Chandra FA, Ahn SS. The effectiveness of percutaneous transluminal angioplasty for the treatment of critical limb ischemia: A 10 year experience. *J Vasc Surg* 2005;41(3):423-35.
- Silver FL, Mackey A, Clark WM, Brooks W, Timaran CH, Chiu D, *et al.* Safety of stenting & endarterectomy by symptomatic status in the carotid revascularization endarterectomy versus stenting trial (CREST). *Stroke* 2011;42(3):675-80.
- Ahn SH, Prince EA, Dubel GJ. Carotid artery stenting: Review of technique and update of recent literature. *Semin Intervent Radiol* 2013 ;30(30):288-296.
- Cardenas DD, Haselkom JK, Mc Elligott JM, Gnertz SM. A bibliography of cost effectiveness practices in physical medicine and rehabilitation: AAPM&R white paper. *Arch Phys Med Rehabil* 2001;82(5):711-9.
- Ostenbrink JB, Tangeldar MJ, Busschbach JJ, van Hout BA, Buskens E, Algra A, *et al.* Cost Effectiveness of oral anticoagulants versus aspirin in patients after inguinal bypass grafting surgery. *J Vasc surg* 2001;34(2):254-62.
- Whatling PJ, Gibson M, Torrii EP, Magcc TR, Galland RB. Iliac occlusions: Stenting or crossover grafting. An examination of patency and cost. *Eur J Vasc Endovasc Surg* 2000;20(1):36-40.

Address for Correspondence:

Dr. Tariq Ashraf, Department of Cardiology, National Institute of Cardiovascular Diseases, Rafiqui (H.J.) Shaheed Road, Karachi-75510-Pakistan,

Cell: +92 322 299 4991, **Email:** tariqkarim313@yahoo.com