

CASE REPORT

SPENT BULLET INJURIES IN THE HEAD AND NECK REGION

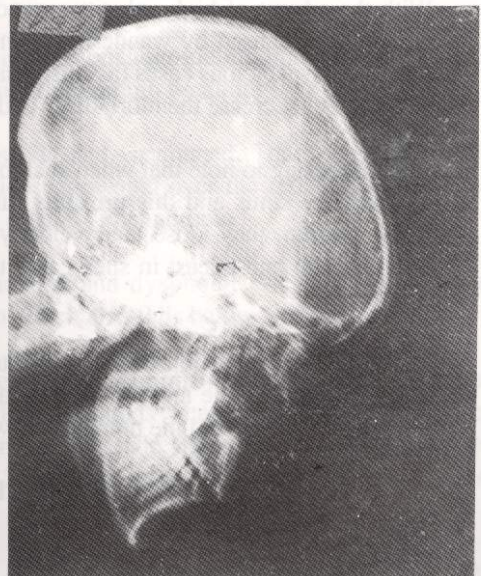
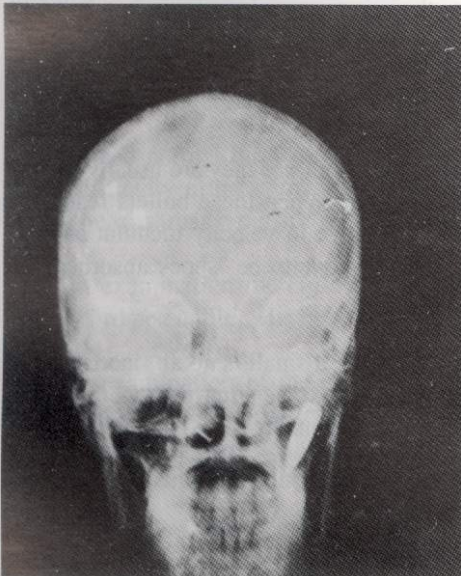
M. Akhtar, G. Nabi, R. Ghani and Gul Mohammad

ABSTRACT :

There is increasing incidence of various injuries caused by wandering spent bullets. These injuries have been encountered in Head and Neck regions, upper limbs and trunk. They can cause severe morbidity and can prove to be fatal. Many such cases have not been reported in literature. There are two reports available in literature, one from Jordan by Hanieh and other from Peshawar (Pakistan) by Rafiq Khan et al. We report an other case of the same nature.

CASE HISTORY :

A 26 years old lady was sitting in the courtyard of her house with her family on 2-9-92 when she felt severe pain in her right orbit. She cried "Oh! my eye has gone" and her husband and other family members looked at her and consoled her that she was alright and there was nothing to be worried. The next morning again she complained of pain and her husband noticed a small wound a the lateral side of her right orbit. He took her to a



From Ayub Medical College, Abbottabad.

MUHAMMAD AKHTAR, MBBS, FCPS, Senior Registrar, ENT Unit.

GHULAM NABI, MBBS, MCPS, Professor, Department of ENT.

REHMAN GHANI, MBBS, FRCS, Assistant Professor, Deptt. of ENT

GUL MOHAMMAD, MBBS, FRCS, Associate Professor, Deptt of Surgery

local Hospital where they found a bullet shadow in the right maxilla. They referred the patient to the D.H.Q. Teaching Hospital, Abbottabad on 7-9-92 where she was admitted in the surgical unit. The surgical people noticed a little epistaxis from right nostril and having found the bullet in right antrum, referred the case to the ENT Unit for removal. The young lady was pregnant for 2.5 months but she was feeling severe facial pain so we decided to remove the bullet from the antrum. The cold-well lucs was done on 9-9-92 under ketamine and oxygen only and bullet was removed. The recovery was smooth, patient was free of pain and she was discharged on next day i.e. 10.9.92.

DISCUSSION :

Foreign Body from a maxillary antrum is removed through cold well-Lucs surgery. Indications ¹ for cold well-Luc are mainly two fold :

1. Diseases of maxillary sinus in which chronic maxillary sinusitis, recurrent. A.C. Polyp, oroantral fistula, different growths and trauma and F.B. in maxillary antrum are common.
2. As an approach to the pterygopalatine fossa for ligation of "artery of epistaxis" and median neurectomy."

CONCLUSIONS :

With the advent of high velocity weapons, there is an ever increasing incidence of different injuries caused by wandering spent bullets. Physician should be aware of this problem and in suspicious cases (as it is usually) one should sort out and manage the case without delay to decrease the morbidity ² and possible catastrophe ³.

It is interesting to note that when such bullets hit on the face they are usually lodged in the maxillary sinus and this prevents further trauma. When these bullets reach the maxillary antrum, they lose their velocity due to change in velocity medium and get lodged in antrum and at least in such cases the sinuses prove to be "shock absorbers" to the cranium.

There can be a question that why not to leave alone a small, smooth, inert foreign body, like a pellet, in the antrum. In our case there was excruciating pain as the bullet was too big for antrum and the pointed end was irritating dental roots, so it was removed.

REFERENCES :

1. Scot, Brown, Disease of the Nose. Page No. 295
2. Rafiq, Khan et. al. The Journal of Laryngology and Otolology December, 1985 Vol 99 PP 1319-23.
3. Haneih. Adult Audiology, Page 174, Scot Brown