

CATARACT SURGERIES BY PHACO-SANDWICH TECHNIQUE THROUGH SCLEROCORNEAL TUNNEL, A COHORT STUDY IN OMAN

Mohammad Naqaish Sadiq, Anant Pai*, Padma Mohan.J.Kurup **

Consultant Ophthalmologist and Head of Department of Ophthalmology, Rustaq General Hospital Sultanate of Oman, * Specialist in Ophthalmology, Sohar Hospital, Sultanate of Oman, ** Epidemiologist, Rustaq General Hospital Sultanate of Oman.

Background: To evaluate the changes in Preoperative and Postoperative keratometry results and rapid visual rehabilitation in Cataract surgery by our phaco-sandwich technique through the self sealing sclero-corneal tunnel incision without phacoemulsification. **Methods:** 96 eyes of 88 patients with age-related cataracts underwent small incision suture less cataract surgery without phacoemulsification. All eyes were operated by the phaco-sandwich technique through sclerocorneal tunnel with 6 mm frown-shaped external scleral incision. 6 mm single piece PMMA lens was implanted in the capsular bag. Patients were evaluated at 1week, 4 weeks and 12 weeks post-operatively. **Results:** Ninety six eyes of eighty eight patients were our cohort. During the first post-operative week 8 eyes (8.3%) had uncorrected visual acuity (UCVA) of 6/6. By the end of 12 post-operative weeks, 33 eyes(34.5%) had UCVA of 6/6. 64 (66.7%), 72(75%) and 80(83.3%) eyes had best correctable visual acuity (BCVA) of 6/6 after 4 weeks, 8 weeks and 12 weeks respectively. 64 (66.7%) eyes after 4 weeks, 72 (75%) after 8 weeks and 80 (83%) after 12 weeks had best correctable visual acuity (BCVA) of 6/6. **Conclusion:** Suture less, small-incision cataract surgery is an economical, safe and effective method of managing cataract cases. This technique also ensures satisfactory and rapid rehabilitation for patients. This procedure can be effectively applied to clear the backlog of cataract-related blindness in places wherein the resources for phaco facilities are not available.

Keywords : Small incision cataract surgery, Phacoemulsification, Phacosandwich

INTRODUCTION

Now-a-days, the trend in cataract surgery is to achieve cataract extraction and intraocular lens (IOL) implantation through the smallest possible incision. This concept of reduction in incision size has played a big role in bringing about faster stability of wound healing and post-operative astigmatism which has helped in early rehabilitation of cataract patients post-operatively. Presently, there are different techniques for achieving this small incision cataract surgery; and they will continue to evolve in future. The popular phacoemulsification is one among them. But it requires costly instrumentation which also needs continuous maintenance. To overcome the limitations of this instrument dependent phaco techniques, instrument independent (i.e. non-phaco) techniques are becoming popular and are being accepted by the cataract surgeons the world over. Though the non-instrumental phaco techniques involve incisions larger than the phaco incisions, the incisions employed in these techniques are secure and optimal to allow the implantation of rigid IOL but without inducing much astigmatic effect.

We present our technique and results following non-phaco small incision cataract surgery in a cohort of 88 patients.

MATERIALS AND METHODS

96 eyes of 88 patients were included in this study. All patients signed the informed consent before surgery.

Only the patients who had age-related cataracts were included in this study. Patients with glaucoma, patients with previous ocular surgery in the operative eye (e.g. filtering surgery) and rigid non-dilatable pupils were excluded. Preoperative assessment included a complete, biomicroscopic examination of anterior and posterior segments, evaluation of cornea, grading of the nucleus and cataract, applanation tonometry, keratometry, and biometry and IOL power calculation.

Surgical Technique: Pupillary dilatation was achieved with 2 instillations each of 1% Tropicamide and 10% Phenylephrine eye drops into the conjunctival cul-de-sac. All patients were operated under per bulbar local anaesthesia (3 ml of 2% Lignocaine + 3 ml of 0.5% Bupivacaine along with 15 Units/ml of Hyaluronidase enzyme). No digital massage or Honnan's balloon were used in order to avoid hypotony of the eye ball, after injecting the anesthetic agent into the orbit. The surgeries were performed by the first 2 authors.

The conjunctiva and Tenon's capsule were dissected from the limbus from 10 O'clock to 2 O'clock. The conjunctiva was dissected upto 4 mm behind the limbus. Minimum wet field cautery was applied to cauterize the bleeding vessels.

Scleral tunnel and side port incision: A 6.0 mm pre-set steel marker was placed 1.5 mm behind the limbus superiorly to mark the site and shape of the frown shaped incision (Fig.No.1). Partial thickness

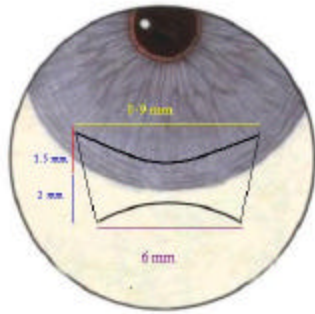


Figure-1

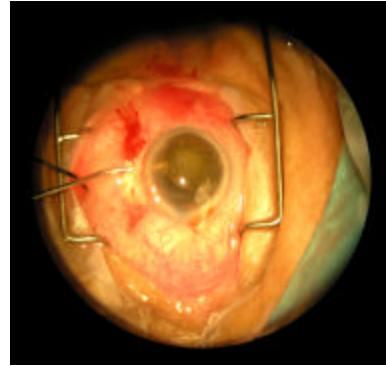


Figure-2

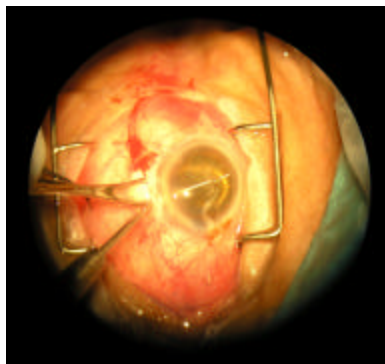


Figure-3

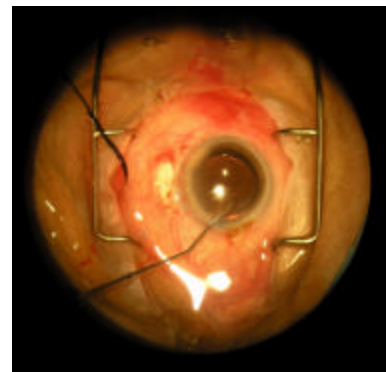


Figure-4

(1/3rd) scleral incision was made with Baevers' blade on the already marked line. Scleral tunnel was created by 2.25mm crescent blade. The tip of the blade is tilted anteriorly to follow the curve of the limbus and dome of the cornea. While taking care to maintain the uniform thickness of dissection, the tunnel was extended upto 1.5 mm of the clear cornea concentric to the limbus and extending 1mm on either sides of the external incision. The anterior chamber was entered with 3.2 mm keratome; the internal wound was enlarged to 8 mm to 9 mm with only forward moment of a 5.2-mm keratome. This architecture of a funnel shaped sclero-corneal tunnel (i.e. wider inside but narrow outside) results in a very strong self-sealing wound at the same time facilitating the delivery of the nucleus. At this stage. Side port entry was made with Beaver's blade 1mm in size at 9 - 9.30 o' clock position...

Trypan blue dye was used under air in cases of mature cataract and Central curvilinear capsulorrhexis (CCC) was performed with 25 G needle under sodium hyaluronate through side port entry. CCC with a minimum size of 67mm was achieved nearly in all patients. Two relaxing

incisions- one at 7 O'clock and one at 12 o'clock were given in cases of small CCC and hard cataracts.

Hydro dissection and nucleus dislocation: Hydro dissection was performed through the 9.30 O' clock side port entry and through the tunnel at 3, 6, 9, and 12O'clock position. No hydro delineation was done. Final hydro dissection at 9 and 12 O'clock was more forceful until a part of nucleus prolapsed or tilted anteriorly into the anterior chamber. Later, with the help of healon cannula nucleus was rotated either clockwise or counterclockwise, while healon was being injected into the capsular bag and into the anterior chamber, simultaneously and with the lens dialer, the nucleus was completely brought into the anterior chamber. (Fig No. 2). Anterior chamber was kept full of viscoelastic during all this procedure.

After prolapsing the nucleus in to anterior chamber, viscoelastic was injected above and below the nucleus. The upper layer shields the endothelium while the lower layer pushes the iris and posterior capsule posteriorly. A specially designed microvectis 4mm wide and 8mm long with corrugations on its upper curved surface was introduced under the nucleus with one hand; and simultaneously Sinsky's hook was introduced with the other hand on

to the front surface of the nucleus but away from the endothelium. Thus the nucleus was sandwiched between these two instruments. While keeping this sandwich away from the corneal endothelium under cover of viscoelastic and well engaged between two instruments, it was easily delivered out of eye through the tunnel by this bimanual phacosandwich technique (Fig-3). The AC was kept deep throughout the procedure to protect the endothelium and the posterior capsule. Most of the cortex was expressed out through viscoexpression by injecting viscoelastic while pressing the inferior lip of the tunnel. The residual cortex was aspirated by Simcoe cannula to achieve a complete cortical clean-up. The viscoelastic was again injected into AC and the capsular bag; and a rigid all PMMA IOL of 6mm optic diameter and of appropriate power was implanted and positioned into the bag (Fig-4).

The tunnel wound is checked for any leak, and hydration of the side port was performed at the end of the procedure. The conjunctival ends on either end were approximated with cautery. All patients received 2 mg of Dexamethasone and 20 mg of Gentamycin, subconjunctivally. The eye was patched by eye pads and an eye shield.

All patients were examined at 1st post-operative day, 1 week, 4 weeks, and 12 weeks after surgery. All patients received topical 0.1% Dexamethasone and 0.3% Ofoxacin, postoperatively for four weeks. Follow-up examinations included a complete biomicroscopic examination, naked eye visual acuity, best correctable visual acuity and keratometry. The data collected by these tests were entered in excel spreadsheets and analyzed using statistical package SPSS. Statistical analysis for the data of these patients was done at 1 week, 4 weeks and 12 weeks visits.

RESULTS

Of the 88 patients, 46 were females and 42 were males. 6 patients had undergone surgery on both sides. Their age ranged from 49 yrs to 73 yrs (mean age 57 yrs). All had their preoperative best corrected visual acuity less than 6/60.

Average surgical time was 25 minutes. All surgeries were uneventful intra-operatively except that in two eyes the posterior capsule (PC) rent with vitreous loss was encountered while performing cortical clean up at 12 o'clock position. This was managed by adequate automated vitrectomy. The IOL implantation was done into the sulcus in these cases. 3 eyes had smaller size CCCs (one had 5 mm CCC and in the remaining two eyes CCC achieved was 4.5 mm) which had to be enlarged by giving 2 relaxing incisions – one at 7 o'clock and the other at 12 o'clock position by the cystitome needle. None

of these 3 eyes had PC tear or vitreous loss. Two eyes had localized Descemet's detachment superiorly which were managed by injecting an adequate sized air bubble in the anterior chamber at the end of the procedure. These 2 cases had corneal edema in the involved area post operatively and it resolved over the next 4 weeks.

Post-operatively, 5 eyes had transient moderate intra-ocular pressure rise on first post operative day that was attributed to retained viscoelastic material. These were successfully managed medically. 5 eyes (in addition to the two cases noted above which had Descemet's detachment) had localized corneal edema superiorly post-operatively in the area of sclero-corneal tunnel incision which cleared by the next postoperative visit at one week. In none of our cases we encountered posterior dislocation of nucleus/cortical matter intraoperatively; or wound leakage, iris prolapse or flat anterior chamber postoperatively.

At the first post-operative week, 8 eyes (8.3%) of the eyes had uncorrected visual acuity (UCVA) of 6/6. By the end of 12 post-operative weeks, 33 eyes (34.5%) had UCVA of 6/6 (Table no. 1a). This indicates a statistically significant increase in the proportion of eyes with UCVA of 6/6 by 12 weeks. 64 eyes (66.7%), 72 eyes (75%) and 80 eyes (83.3%) had best corrected visual acuity (BCVA) of 6/6 at, 8 and 12 weeks respectively. The reasons for not achieving BCVA of 6/6 in 16 of the cases have been shown in pie chart (Fig. 5). 11 eyes had trichomatous corneal opacities, 2 eyes had diabetic maculopathies, 1 eye had cystoid macular edema and 2 eyes had age related macular degeneration.

The mean preoperative astigmatism of 96 patients was 0.18 (SD=1.45). As shown in table no.2, the post-operative astigmatism at 1, 4 and 12 week was 0.38(SD=1.5), 0.26 (SD=1.4) and 0.22 (SD=1.3) respectively. It was found that there was no statistically significant difference between preoperative and postoperative astigmatism at 1 week (t=0.9 p=0.3), at 4 week (t=1.3 p=0.1) and at 12 week (t=0.9 p0.35).

Table 1: Results of Postoperative Visual acuity testing

(Preoperatively all had a best corrected VA of < 6/60)

Table 1. A Uncorrected Visual Acuity of 6/6 (Total Number N = 96)

Post Operative duration	Number of eyes with VA of 6/6	%
At 1 week	8	8.3
At 4 weeks	12	12.5
At 12 weeks	33	34.37

Chi. Sq value=25.02, d.f=2, p<0.001

Table 1. B Best Corrected Visual Acuity of 6/6 (n = 96)

Post Operative duration	Number of eyes with VA of 6/6	%
At 1 week	64	66.7
At 4 weeks	72	75
At 12 weeks	80	83.3

Chi. Sq value=7.1, d.f=2, p=0.03

Table 2: Preoperative & Post operative Astigmatism (1, 4 and 12 weeks)

	No. of Eyes	Mean± S.D
Preoperative	96	0.18 ± 1.45
Postoperative at week 1	96	0.38 ± 1.5
Postoperative at week 4	96	0.26 ± 1.4
Postoperative at week 12	96	0.22 ± 1.3

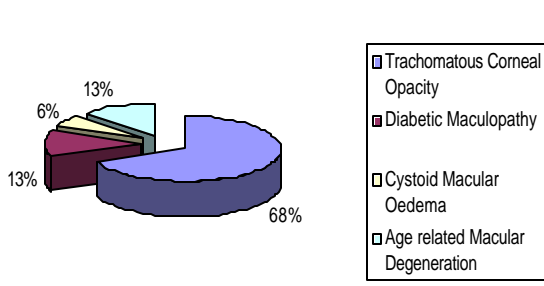


Fig- 5: Causes for final BCVA <6/6

DISCUSSION

Senile age-related cataract causes about 50% of world blindness¹. The techniques of cataract surgery have changed enormously in last few years and will undoubtedly continue to evolve at an ever increasing pace. Nowadays, technologies with the use of small self-sealing incisions have taken a major lead in cataract surgery. During past few years phacoemulsification has largely replaced ab-externo extracapsular cataract extraction with posterior chamber intraocular lenses (ECCE+PC IOL) with sutures. However because of expensive machine and its consumable, costly maintenance and difficult learning curve phacoemulsification has played a very limited role in reduction of cataract blindness in low income countries.^{2,3,4} Since the phaco procedure is wholly machine dependent, an unfortunate machine failure or its malfunction in the middle of the surgery can also make the operating surgeon land into precarious and dangerous situations.

Phaco-instrument independent, i.e.(non-phaco or manual phaco) techniques based on the concept of scleral tunnel enable the surgeon to get the equally good results as by instrumental

phacoemulsification with many additional advantages viz. a universal applicability to all grades of cataract, economical and relatively safer and easier learning curve. Many different techniques exist for the nuclear management for the non-phaco small incision technique. The most popular among them are: Michael Blumenthal’s anterior chamber maintainer (ACM) technique, Luther Fry’s phacosandwich technique³, Peter Kansas’ phacofracture technique, manual multiphacofragmentation and irrigating vectis technique⁴⁻⁵.

In this series, we adopted the phaco-sandwich technique. We chose this technique because this technique ensures the safe nuclear delivery with minimal iatrogenic insult to the corneal endothelium. The anterior instrument (i.e. the Sinsky hook/lens dialer) will help in protecting the endothelium and the specially designed corrugated microvectis will ensure the controlled delivery of the nucleus through the tunnel. The enlarged internal tunnel allows the nucleus to rest in it and to come out in toto without damaging endothelium. We chose the frown shaped external incision since it is associated with minimum surgically induced astigmatism (SIA).⁶ We have also seen in this series that there was no any significant change in astigmatism following the surgery. The statistical analysis showed no significant difference between preoperative and postoperative astigmatism at 1 week (t=0.9, p=0.3), at 4 weeks (t=1.3, p=0.1) and at 12 weeks (t=0.9, p=0.35)

In this technique it is the stability of surgeon’s two hands which accounts for the safe removal of the nucleus without insulting endothelium and posterior capsule. Neither there is any chance of nucleus drop. In cases of very large and hard cataract we recommend that tunnel may be enlarged up to 7mm but one suture should be placed to neutralize surgically induced astigmatism⁵.

When compared to phacoemulsification, this non-phaco small incision technique has many advantages. This can be adopted safely in hyper mature cataracts where zonules are weak and in very hard nuclear cataracts. Also, the chances of the most dreaded complication of posterior dislocation of the nucleus or the nuclear fragment which can be encountered during the phacoemulsification is not encountered during this non-phaco technique. Since none of any extraneous energy (i.e. ultrasound energy) is used during this procedure, one will not encounter any complications related to ultrasound energy viz. any corneal burns or iris chaffing or any additional damage to the adjacent normal tissues. Endothelial cell loss is found to be equal in both phaco and the non-phaco small incision technique⁷. We have not done the objective specular microscopy for endothelial cell count in our patients. The other

advantage over the phaco technique is the lesser cost involved since this technique does not require expensive instrumentation.

Our technique can replace the conventional ECCE method and can achieve postoperative results similar to those of instrumental phacoemulsification. The advantages of this small incision technique over the conventional ECCE are: reduced surgical time⁸, no wound leakage and no iris prolapse, no flat anterior chamber postoperatively⁹, early stabilization of postoperative refraction with faster visual recovery¹⁰ and a lower incidence of fibrinous iritis than ECCE surgery¹¹. Most investigators have observed that it takes 1 to 4 weeks to achieve a stable postoperative refraction¹², and there is minimal surgically induced astigmatism⁵. All these facts have been reinforced by this study.

To conclude, this technique is an effective, fast, and economical alternative ensuring satisfactory astigmatism free rehabilitation for the patients¹³. We recommend that, since this technique does not require expensive instrumentation and visual recovery is as rapid as that of phacoemulsification, one can safely and reliably employ this technique to achieve small incision cataract surgery most of the time if not 100% of the time¹⁴ while addressing the backlog of cataract related blindness.¹⁵

REFERENCES

1. Stanford-Smith J. Sutureless Cataract Surgery: Principles and Steps. *Community Eye Health* 2003, 16(48):51-53.
2. Natchiar G, Robin AL, Thulasiraj R. Attacking the backlog of India's curable blind; the Aravind Eye Hospital model. *Arch Ophthalmol.* 1994; 112:987-993.
3. Fry LL. The Phaco sandwich technique. In: Rozakis GW(Ed), *Cataract Surgery: Alternative Small incision techniques.* Thorofare NJ Slack1990; 91-110.
4. Gutierrez-Carmona FJ. Manual multiphacofragmentation through a 3.2 mm clear corneal incision. *J Cataract Refract Surg* 2000; 26:1523-1528.
5. Zvia Burgansky MD, ItzhakIsakov MD, Haggay Avizmer MD, Elisha Bartov MD. Minimal astigmatism after sutureless planned extracapsular cataract extraction. *J Cataract Refract Surg* 2002; 28:499-503.
6. Singer JA. Frown incision for minimizing induced astigmatism after small incision cataract surgery with rigid optic intraocular lens implantation. *J Cataract Refract Surg* 1991; 17: 677-688 .
7. Hayashi K, Hayashi H, Nakao F, Hayashi F. Risk factors for corneal endothelial injury during phacoemulsification. *J Cataract Refract Surg* 1996; 22:1079-84.
8. Fish JR. Creation of a no-stitch cataract incision. *J Cataract Refract Surg* 1991;17:713-15
9. Atisub T, Thongplengsri C, Panegputhiopong P. Small Incision Sutureless Cataract Surgery with and without Phacoemulsification, *Thai J Ophthalmol* 1992; 6(1):31-39.
10. Anders N, Pham DT, Antoni HJ, Wollensk J. Postoperative astigmatism and relative strength of tunnel incision: a prospective clinical trial. *J Cataract Refractive Surg* 1997;23: 332-36.
11. Guzek JP, Ching A. Small-incision manual extracapsular cataract surgery in Ghana, West Africa. *J cataract Refract Surg.* 2003 Jan;29(1):57-64.
12. Sinskey RM, Stoppel JO. Induced astigmatism in a 6.0 mm no-stitch frown incision. *J Cataract Refract Surg* 1994; 20: 406-409
13. Sood A, Kumar S, Badhu B, Kulshreshtha V. Astigmatism and Corneal Thickness in Conventional Large Incision Versus Manual Small Incision Cataract Surgery. *Asian J Ophthalmology* 2002; 4(4):2-6.
14. Thomas R, Kuriakose T, George R Towards Achieving small-incision Cataract Surgery 99.8% of the time. *Indian J Ophthalmol* 2000; 48(2):145-51
15. Albrecht Hennig. Sutureless Non-phaco Cataract Surgery: A solution to reduce worldwide cataract blindness. *Community Eye Health* 2003; 16(48):49-51.

Address for correspondence: Dr. Mohammad Naqaish Sadiq Consultant and Head, Department of Ophthalmology, Rustaq General Hospital P.O.Box.67, PC 329 Ministry of Health, Sultanate of Oman.
E mail: naqaishsadiq@yahoo.com