

**CASE REPORT****A CASE REPORT OF GASTROPARESIS SECONDARY TO ACUTE RENAL FAILURE****Fahim A, Macleod D\***

Department of Respiratory Medicine, Castle Hill Hospital, Cottingham, East Yorkshire, UK, \*Staffordshire General Hospital, Stafford UK

A 45-year-old female with a background of poorly differentiated ovarian adenocarcinoma treated with bilateral salpingo-oophorectomy presented with one week history of nausea, vomiting and decreased urine output. On examination, she was mildly dehydrated but haemodynamically stable. Abdominal examination revealed tender swelling in upper abdomen. Biochemistry revealed that she had acute renal failure and interestingly the acute renal failure was out of proportion to the degree of dehydration. Abdominal ultrasound showed marked distension of the stomach without any evidence of renal tract obstruction. She was aggressively treated with volume replacement and careful monitoring of input and output. She responded very well to fluid replacement and her renal failure resolved within four days of treatment. This case illustrates a case of acute renal failure secondary to gastroparesis which resolved after treatment of renal failure. Patients with chronic renal failure are prone to develop gastroparesis but it is extremely rare to have gastric stasis following acute renal failure. This case also illustrates the importance of aggressive treatment of a reversible but potentially fatal medical condition which could have been easily overlooked in view of patient's poorly differentiated ovarian cancer.

**Keywords:** Acute Renal Failure, Gastroparesis, Ovarian adenocarcinoma

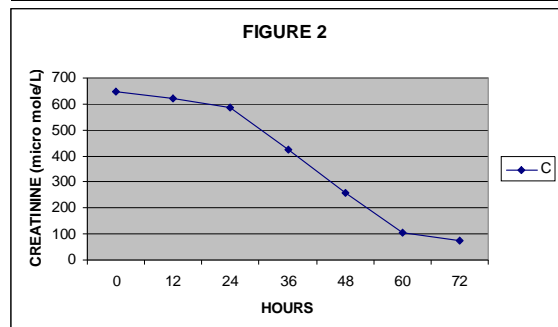
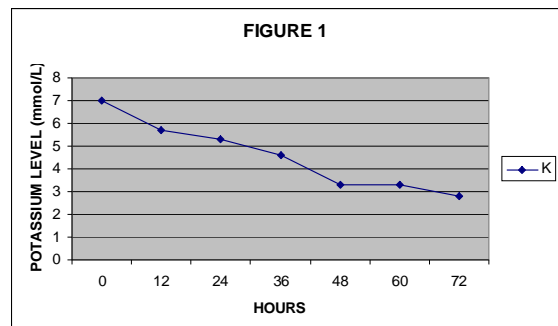
**CASE REPORT**

A 45 year old lady presented with 1 week history of nausea, vomiting and decreased urine output. She had a background of poorly differentiated bilateral ovarian mucinous adenocarcinoma treated with bilateral salpingo-oophorectomy and chemotherapy. On examination, she was mildly dehydrated but haemodynamically stable with following vital signs. Pulse 90/min, BP 120/80, RR 16/min, Temp 36. JVP was not visible. On abdominal examination, she had tender swelling in upper abdomen and an ileostomy from bowel operation. Rest of the examination was completely normal.

Laboratory investigations revealed that she was in acute renal failure with hyperkalemia. Renal function was urea 52.6 mmol/l, creatinine 649  $\mu$ mol/l, K 7 mmol/l, Na 116 mmol/l. Arterial blood gases showed pH 7.46,  $P_{CO_2}$  5.6 kpa,  $P_{O_2}$  15 kpa and bicarbonate of 30. Rest of the blood tests including FBC, clotting, LFTs and calcium were normal. A working diagnosis of pre-renal failure secondary to vomiting was made but we organized an ultrasound of abdomen and renal tract in view of abdominal mass and to rule out renal tract obstruction as patient's renal failure was out of proportion to the degree of dehydration. Ultrasound showed normal renal tract without any evidence of hydronephrosis but interestingly, it revealed that the stomach was markedly distended with fluid.

This patient was treated aggressively with rapid volume replacement via central line and close monitoring of CVP and urine output and fortunately patient improved very quickly and her renal function

and potassium normalized over the next 3 days. Figure-1 and 2.

**DISCUSSION**

This case illustrates an episode of gastroparesis following acute renal failure, which resolved after treatment of renal failure. There are different causes of gastroparesis including idiopathic or attributable to neuropathic or myopathic abnormalities, such as diabetes mellitus, chronic renal failure, postvagotomy,

postviral infection, and scleroderma. Gastroparesis has also been reported in multiple sclerosis.<sup>1</sup> Gastroparesis associated with autonomic neuropathy is found in about 50% of patients with type 1 and type 2 diabetes. In some diabetic patients, gastroparesis may contribute to erratic glucose excursions, with precocious postprandial hypoglycaemia, late hyperglycaemia or delayed recovery from hypoglycaemia after carbohydrate ingestion.<sup>2</sup> Scintiscanning at 15-minute intervals for 4 hours after food intake is considered the gold standard for measuring gastric emptying in detail<sup>3</sup>. Patients with chronic renal failure are prone to develop gastroparesis, it is very rare to have gastric stasis following acute renal failure. There has been no case of gastroparesis reported due to acute renal failure in literature. This case also illustrates the importance of aggressive treatment of a reversible but potentially fatal medical condition which could have been easily overlooked in view of patient's poorly differentiated ovarian cancer.

#### **Therapeutic approaches**

The prokinetic agents, metoclopramide, domperidone, and erythromycin are successful in controlling symptoms in the majority of patients with gastroparesis

due to diabetes. In addition to prokinetic drugs, dietary and behavioural modification and surgical interventions have been used in managing patients with gastroparesis. Although mild gastroparesis is usually well managed with these treatment options, severe gastroparesis may be very difficult to control and may require referral to a specialist centre if symptoms are intractable despite pharmacological therapy and dietetic support. New advances in drug therapy, botulinum toxin injection, and gastric electrical stimulation techniques have been introduced and might provide new hope to patients with refractory gastroparesis.<sup>4</sup>

#### **REFERENCES**

1. Raghav S, Kipp D, Watson J, Spring W. Gastroparesis with Multiple Sclerosis. *Mult Scler* 2006;12(2):243.
2. Stassen MP. Diabetic Gastroparesis. *Rev Med Liege*. 2005;60(5-6):509-15.
3. Michael Camiller. Diabetic Gastroparesis. *N Engl J Med* 2007;356:820-9.
4. Thomas L. Abell, Scott Malinowski, Pharm D, Anil Minocha. Nutrition Aspects of Gastroparesis and Therapies for Drug-Refractory Patients. *Nutrition in Clinical Practice* 2006;21(1):23-33.

---

#### **Address for Correspondence:**

**Dr. A Fahim**, Specialist Registrar, Respiratory Medicine, Castle Hill Hospital, Cottingham, East Yorkshire HU16 5JQ UK.

Email: drfahim77@hotmail.com