

## CASE REPORT

## N-BUTYL-2-CYANOACRYLATE AND LIPOIDOL PULMONARY EMBOLISM (GLUE EMBOLISM)

Asim Javed, Amjad Salamat\*

Department of Medicine, Combined Military Hospital, Rawalpindi, \*Gastroenterologist, Military Hospital Rawalpindi

Glue embolisation is a rare happening and many clinicians who evaluate patients for post sclerotherapy problems may be unaware of this complication. We present a case of pulmonary embolism in a patient of cirrhosis liver secondary to gastric variceal sclerotherapy with N-Butyl-2-cyanoacrylate and lipoidol solution. This is also called glue embolism.

**Keywords:** Sclerotherapy, Cyanoacrylate, Lipoidol, Embolism

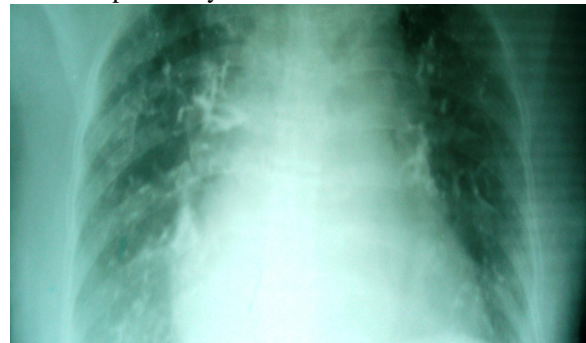## INTRODUCTION

Gastric variceal bleeding is a serious complication of portal hypertension and the significant morbidity and mortality resulting from this bleed presents a challenge for gastroenterologists. Endoscopic treatment with the tissue glue cyanoacrylate is considered by many clinicians, to be the optimal initial treatment for bleeding gastric varices.<sup>1</sup> Endoscopic sclerotherapy has a potential risk of migration of the sclerosant to the systemic venous circulation in patients with varices associated with a gastrosystemic venous shunt, which may result in a pulmonary embolism.<sup>2,3</sup> Glue embolisation is a rare happening and therefore many clinicians who evaluate patients for post sclerotherapy problems may be unaware of this complication. We present such a case of cirrhosis liver with gastric varices which were injected with sclerosant N-butyl-2-cyanoacrylate and lipoidol solution and led to pulmonary embolism. We believe that this is probably the first case being reported for publication in Pakistan.

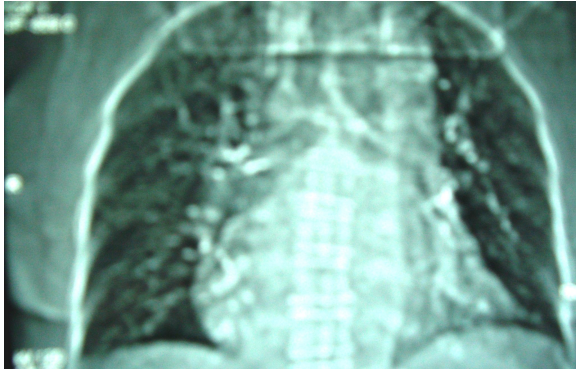
## CASE REPORT

A 60-years-old lady, suffering from cirrhosis liver secondary to hepatitis C infection (Child Turcotte Pugh class C) presented to the emergency department with two days history of melena and inversion of sleep rhythm. On examination she had stable vital signs with normal respiratory and cardiovascular systems. Abdominal examination revealed ascites with mild splenomegaly. Her blood counts showed pancytopenia with deranged prothrombin time. Chest X-ray did not reveal any abnormality. On admission to the intensive care unit, the patient was given terlipressin, packed red blood cells, plasma, platelets and lactulose. Upper GI endoscopy showed portal hypertensive gastropathy and large gastric varices in the cardia. Two days later endoscopic sclerotherapy was performed with injections of a solution containing 4 ml of N-butyl cyanoacrylate and 8 ml lipoidol (a lipid based radiological contrast agent to prevent premature polymerization of the glue). A 19-gauge needle with 10 ml syringe was used to inject the large gastric varices. Increased quantity of solution had to be given as the patient coughed at the wrong time during the procedure and there was a lot of spurring of blood. Injection was

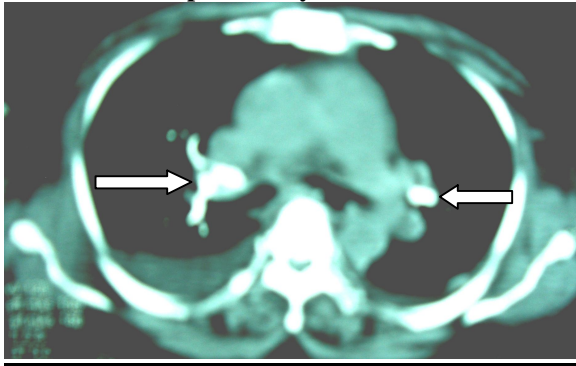
completed and blood was aspirated. Haemostasis confirmed and varices had collapsed. On the second day of procedure patient started having mild cough with low grade fever and became dyspnoeic and required supplemental oxygen therapy. She developed tachycardia and became tachypnoeic. On examination of her chest there were bilateral ronchi with few crepts on the left lower side. Her D-dimers were more than 2000. Chest X-ray showed bilateral multiple tubular and nodular radio-opaque lesions in the perihilar regions and all lung zones. A provisional diagnosis of N-butyl cyanoacrylate and lipoidol pulmonary embolism was made and patient was given supplemental oxygen therapy. CT scan of the chest showed linear hyperdense shadows in both pulmonary arteries and in some of their branches. CT scan of the abdomen revealed varicose vascular channels in the splenic hilum, leinorenal and gastroleinal ligaments. Left gastric veins and gastroepiploic veins were also dilated. Tubular areas of increased attenuation were also seen in some of the left gastric veins, in the wall of lesser curvature of stomach and gastroleinal ligaments thus confirming lipoidol emboli in the upper abdominal veins. A V/Q scan, and 2-D echo were also planned but patients condition kept deteriorating and she again started having melena and went into hepatic encephalopathy grade IV. She also developed DIC. Patient was restarted on I/V terlipressin and transfused packed red blood cells along with plasma and platelets with appropriate antibiotic cover and other supportive therapies. Repeat upper GI endoscopy was planned but patient went into cardiopulmonary arrest and could not be revived.



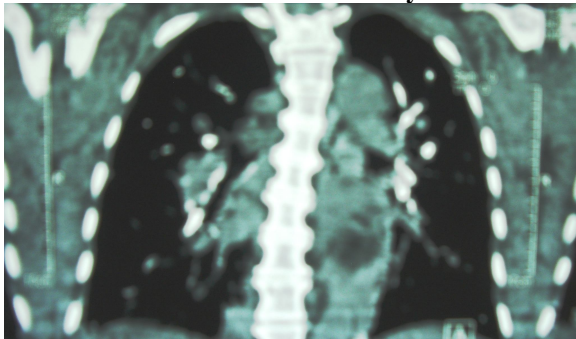
**Figure-1: Chest X-ray showing bilateral lipoidol pulmonary emboli**



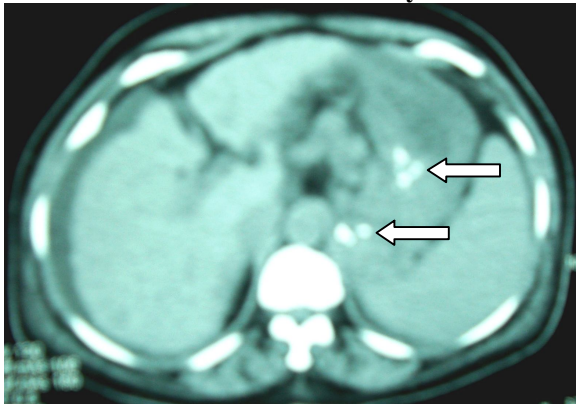
**Figure-2: Scannogram showing bilateral lipiodol pulmonary emboli**



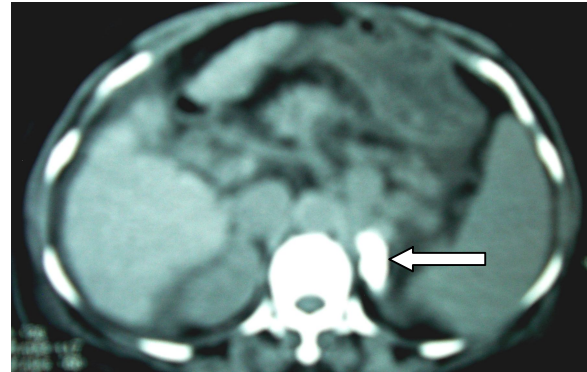
**Figure-3: Lipiodol embolism in pulmonary vasculature bilaterally**



**Figure-4: Lipiodol embolism in pulmonary vasculature bilaterally**



**Figure-5: Ascites + shrunken liver + splenomegaly + lipiodol embolism**



**Figure-6: Gastric varices + lipiodol embolism**

## DISCUSSION

In patients with portal hypertension, acute gastro-oesophageal variceal bleeding is one of the main causes of death. Therefore, the treatment and prevention of variceal bleeding are important for successful patient management. For this reason, the demand for palliative treatment of acute gastro-oesophageal variceal bleeding continually increases. Various treatment modalities such as pharmacological therapy, balloon tamponade, endoscopic injection sclerotherapy (EIS), and endoscopic variceal ligation have all been used for this purpose.<sup>4</sup> In asymptomatic portal hypertensive patients who underwent endoscopic surveillance for varices, gastric varices were detected less commonly than oesophageal varices. The risk of gastric variceal bleeding is also less but whenever bleeding occurs, it is dangerous and may be fatal.<sup>5</sup> Unlike oesophageal varices, endoscopic technique to control gastric variceal bleeding is very difficult due to the awkward position of the scope. All therapeutic devices have to come from retroflex position. In addition, blood in the fundus may obscure the view. Although transjugular intrahepatic portosystemic shunt (TIPS) is used in many centres to treat gastric varices, endoscopic treatment with the tissue glue cyanoacrylate (N-butyl-2-cyanoacrylate) has been used successfully in many countries for 20 years and is considered by many clinicians to be the optimal initial treatment for bleeding gastric varices.<sup>1,6</sup> The rate for primary haemostasis with cyanoacrylate injection is consistent with the reported rate of 90% to 97% even in Pakistan as in other countries.<sup>7,8</sup> The tissue glue, N-butyl-2-cyanoacrylate, is a watery solution that polymerizes and hardens instantaneously, within 4 seconds, on contact with blood.<sup>9</sup> There have been reports of needles becoming stuck in the N-butyl-2-cyanoacrylate and subsequent tearing of the vessel on withdrawal of the needle.<sup>10</sup> To prevent this, it is necessary to dilute it with oily contrast agent Lipiodol. Patients with allergies to iodine should not receive this therapy because Lipiodol is an iodized oil emulsion.<sup>11</sup>



This dilution also allows for visualization when using fluoroscopy to localize the injection. The larger volume being injected and the delayed polymerization may increase the risk of embolization.<sup>12</sup> In the study by Hwang *et al*, the volume of injected N-butyl-2-cyanoacrylate plus iodized oil was a predictor of embolization.<sup>12</sup> Our patient received a total of 4mL of N-butyl-2-cyanoacrylate glue in solution with 8 ml of lipiodol. She had to be given more than normal amount of the solution due to the bleeding that took place during the procedure as a result of her coughing. According to Nasim Mahmoudi and J Scott Whittaker it is important not to inject more than 1 ml of Histoacryl/Lipiodol at a time to avoid embolisation. However, several separate injections can be made into one varix in one sitting.<sup>11</sup> Reported complications after EIS include dysphagia, sepsis, and fever.<sup>15</sup> Occasionally, serious complications such as embolization to the brain<sup>14</sup>, portal vein<sup>15</sup>, and lung<sup>19</sup> have been reported. Our patient developed sepsis (DIC) and pulmonary embolism as a complication of the procedure. However, the reported severity of *n*-butyl-2-cyanoacrylate pulmonary embolism (PE) following EIS has varied from asymptomatic<sup>17</sup> to fatal.<sup>18</sup> When fever, cough, tachycardia, pleuritic chest pain, or dyspnoea develop after endoscopic injection therapy with cyanoacrylate, chest radiography or non-contrast-enhanced computed tomography frequently allows diagnosis of pulmonary emboli.<sup>12,19</sup> Systemic embolization of cyanoacrylates appears to occur most commonly via the gastrosplenic and splenorenal veins<sup>12,20</sup> as was also evidenced in our patient. The lungs typically filter most of the emboli; however, systemic embolization to the splenic, cerebral, and coronary arteries has been described, possibly through an arteriovenous malformation in the lungs or paradoxical embolization through atrial septal defect.<sup>19</sup> Cyanoacrylate embolism is difficult to diagnose with computed tomographic angiography because radiopaque emboli are masked by the contrast material. It is important to distinguish these emboli from conventional thromboemboli because 'glue emboli' require only symptomatic treatment.

## REFERENCES

1. Mahadeva S, Bellamy MC, Kessel D, Davies MH, Millson CE. Cost-effectiveness of N-butyl-2-cyanoacrylate (histoacryl) glue injector versus TIPS in the management of acute gastric variceal bleeding. *Am J Gastroenterol* 2003;98:2688-93.
2. Hwang SS, Kim HH, Park SH, Kim SE, Jung JI, Ahn BY, *et al*. N-butyl-2-cyanoacrylate pulmonary embolism after endoscopic injection sclerotherapy for gastric variceal bleeding. *J Comput Assist Tomogr* 2001;25:16-22.
3. Irisawa A, Obara K, Sato Y, A. Saito, H. Orikasa, H. Ohiro, *et al*. Adherence of cyanoacrylate which leaked from gastric varices to the left renal vein during endoscopic injection sclerotherapy: a histopathologic study. *Endoscopy* 2000;32:804-6.
4. D'Amico G, Pagliaro L, Bosch J. The treatment of portal hypertension: a meta-analytic review. *Hepatology* 1995;22:332-54.
5. Sarin SK, Lahoti D, Saxena SP, Murthy NS, Makwana UK. Prevalence, classification and natural history of gastric varices: a long-term follow-up study in 568 portal hypertension patients. *Hepatology* 1992;16:1343-9.
6. Akahoshi T, Hashizume M, Shimabukuro R, K. Tanoue, M. Tomikawa, K. Okita, *et al*. Long-term results of endoscopic Histoacryl injection sclerotherapy for gastric variceal bleeding: a 10-year experience. *Surgery*. 2002;131(Suppl 1):S176-S181.
7. Huang YH, Yeh HZ, Chen GH, Chang CS, Wu CY, Poon SK, *et al*. Endoscopic treatment of bleeding gastric varices by N-butyl-2-cyanoacrylate (Histoacryl) injection: long-term efficacy and safety. *Gastrointest Endosc* 2000;52:160-7.
8. Khalid Mumtaz, Shahid Majid, Hasnain A Shah, Kashif Hameed, Ashfaq Ahmed, Saeed Hamid, *et al*. Prevalence of gastric varices and results of sclerotherapy with N-butyl 2 cyanoacrylate for controlling acute gastric variceal bleeding. *World J Gastroenterol* 2007;28;13(8):1247-51.
9. Anderson JM, Gibbons DF. The new generation of biomedical polymers. *Biomater Med Devices Artif Organs*. 1974;2:235-48.
10. D'Imperio N, Piemontese A, Baroncini D, Billi P, Borioni D, Dal Monte PP, *et al*. Evaluation of undiluted N-butyl-2-cyanoacrylate in the endoscopic treatment of upper gastrointestinal tract varices. *Endoscopy*. 1996;28:239-43.
11. Nasim Mahmoudi, J Scott Whittaker. Glueing of fundal varices. *Can J Gastroenterol* 2007;20:691-3.
12. Hwang SS, Kim HH, Park SH, Kim SE, Jung JI, Ahn BY, *et al*. N-butyl-2-cyanoacrylate pulmonary embolism after endoscopic injection sclerotherapy for gastric variceal bleeding. *J Comput Assist Tomogr* 2001;25:16-22.
13. Gotlib JP. Endoscopic obturation of esophageal and gastric varices with a cyanoacrylic tissue adhesive. *Can J Gastroenterol* 1990;9:637-8.
14. See A, Florent C, Lamy F, Levy VG, Bouvry M. Cerebrovascular accidents after endoscopic obliteration of oesophageal varices with isobutyl-2-cyanoacrylate in 2 patients. *Gastroenterol Clin Biol* 1986;10:604-7.
15. Moustafa I, Omar MM, Nooh A. Endoscopic control of gastric variceal bleeding with butyl cyanoacrylate. *Endoscopy* 1993;25:A11.
16. Thakeb F, Kader S, Salama Z, Salma H, Abdel R, Abdel KS, *et al*. The value of the combined use of n-butyl-2-cyanoacrylate and ethanolamine oleate in the management of bleeding esophagogastric varices. *Endoscopy* 1993;25:A5.
17. Takasugi JE, Shaw C. Inadvertent butylate pulmonary embolization: a case report. *J Thorac Imag* 1989;4:71-3.
18. Moustafa I, Omar MM, Nouh A. Endoscopic control of gastric variceal bleeding with butyl cyanoacrylate in patients with schistosomiasis. *J Egypt Soc Parasitol* 1997;27:405-10.
19. Roesch W, Rexroth G. Pulmonary, cerebral and coronary emboli during acrylate injection of bleeding fundic varices. *Endoscopy*. 1998;30:S89-S90.
20. Imazu H, Matsui T, Kobayashi Y, Noguchi R, Miyamoto Y, Kawata M, *et al*. Balloon catheter-assisted endoscopic sclerotherapy for gastric fundal varices using alpha-cyanoacrylate monomer. *J Clin Gastroenterol* 2001;33:49-52.

## Address for Correspondence:

**Dr. Asim Javed**, House No. 11, St. 12, Sector C, DHA-I, Phase 1, Morgah, Rawalpindi. Tel: +92-51-5788555  
Email: doctorasimjaved@gmail.com