

CASE REPORT

DUAL PHASE MIBI SCINTIGRAPHY IN DIAGNOSIS OF PARATHYROID ADENOMA FOLLOWED BY ULTRASOUND GUIDED PERCUTANEOUS ALCOHOLIC ABLATION

Shakil Ahmad, Amjad Aziz Khan Asif Jielani, Kamran Khan, Tatheer Fatima, Nadeem Zia, Mazhar ud Duha, Abdul Samad, Khalid Memon

Department of Nuclear Medicine, Institute of Nuclear Medicine, Oncology and Radiotherapy (INOR), Mansehra Road Abbottabad, Pakistan

Primary Hyperparathyroidism (HPT) is an inappropriate hyper secretion of parathyroid hormone (PTH). Primary HPT is caused by parathyroid adenoma in 80-85% of patients. Clinical manifestations are kidney stones, abdominal groans, painful bones, psychic moans, and fatigue overtones. Ultrasonography is widely used in suspected cases for localization of parathyroid adenoma. There is considerable intra-observer variation and it is difficult for ultrasound alone to differentiate parathyroid lesion from that of thyroid. Dual phase Tc-99m MIBI scintigraphy for detection of parathyroid adenomas has sensitivity and specificity values ranging from 82% to 100% and from 89% to 100%, respectively. Percutaneous ethanol injection for parathyroid glands can be applied effectively in selected cases when surgery is unadvisable either for technical reasons (e.g., recurrence of hyperplastic glands in the neck after subtotal surgery or intrathyroidal parathyroid tumors) or the poor clinical state of the patient.

Keywords: Parathyroid Adenoma, MIBI Scintigraphy

INTRODUCTION

Primary Hyperparathyroidism (HPT) is an inappropriate hyper secretion of parathyroid hormone (PTH). The elevated PTH levels cause hypercalcemia and hypophosphatemia. Primary HPT is caused by parathyroid adenoma in 80-85% of patients, by multiple parathyroid adenomas in 2-3%, by parathyroid hyperplasia in 10-15%, and by parathyroid carcinoma in 2-3% of patients.¹

Clinical manifestations are kidney stones, abdominal groans, painful bones, psychic moans, and fatigue overtones. However the patient may be asymptomatic and diagnosed during routine blood test screening. The diagnosis is established biochemically. In primary Hyperparathyroidism, patients tend to have increased PTH level and hypercalcaemia. Bone scan is used to help differentiate the causes of hypercalcaemia.

Ultrasonography is widely used in suspected cases for localization of parathyroid adenoma and is capable of differentiating parathyroid from thyroid abnormalities. Ultrasound has also advantage of not using any radiation. Reported sensitivity and specificity of ultrasound in detection of adenoma in primary hyperparathyroidism is between 30-90%.² However it is dependent on skill of the operator and sensitivity of the equipment. There is considerable intra-observer variation and it is difficult for ultrasound alone to differentiate parathyroid lesion from that of thyroid.

Tc-99m MIBI (Technetium 99m methoxyisobutylisonitrile) being lipophilic, monovalent cationic which localizes in parathyroid and thyroid tissue depending on blood flow and intracellular mitochondrial concentration. Tc-

99m MIBI is widely used for the pre-operative localization of abnormal parathyroid tissue in patients with primary hyperparathyroidism. Dual phase scintigraphy is based on the fact that Tc-99m MIBI washes out more rapidly from the thyroid gland than from abnormal parathyroid tissue.³ This technique for detection of parathyroid adenomas has sensitivity and specificity values ranging from 82% to 100% and from 89% to 100%, respectively.⁴

Bilateral neck exploration has long been considered as gold standard. However with pre-operative imaging techniques minimally invasive focused surgery is emerging. Per-cutaneous ethanol injection under ultrasound guidance is emerging as alternative to reduce the size the adenoma and alleviate symptoms and is proving simple, rapid and save for this purpose.⁵

CASE REPORT

HZ a 26 years old female presented with abdominal pain and vomiting. When serological tests were done it was revealed that her serum calcium was elevated up to 18 mg/dl (normal range 8.6–10.5 mg/dl) and PTH level was also raised up to 969 pg/ml (normal 16–87 pg/ml). On the basis of clinical features and laboratory test her ultrasound of neck was advised for evaluation of parathyroid gland. A hypo echoic parathyroid nodule was appreciated in posterior-lateral aspect of left thyroidal lobe measured up to 21.1×13.7 mm (Figure-1).

Dual phase parathyroid MIBI scan was done for localizing suspected parathyroid adenoma on ultrasound. Patient was injected IV 740 MBq (20 mCi) ^{99m}Tc-MIBI. Images were acquired at 20 min (immediate phase) and after two hrs (delayed phase).

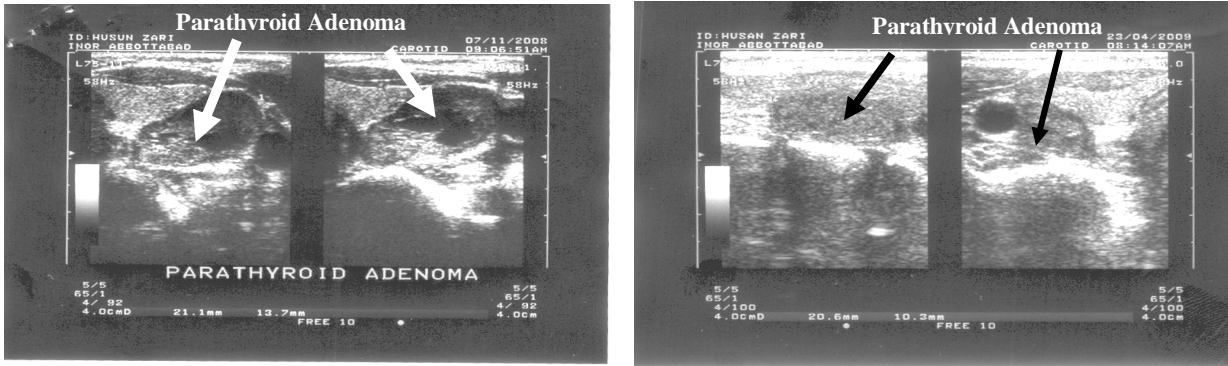


Figure-1: Ultrasonography showing hyper echoic nodule at postero-lateral aspect of left Thyroid lobe

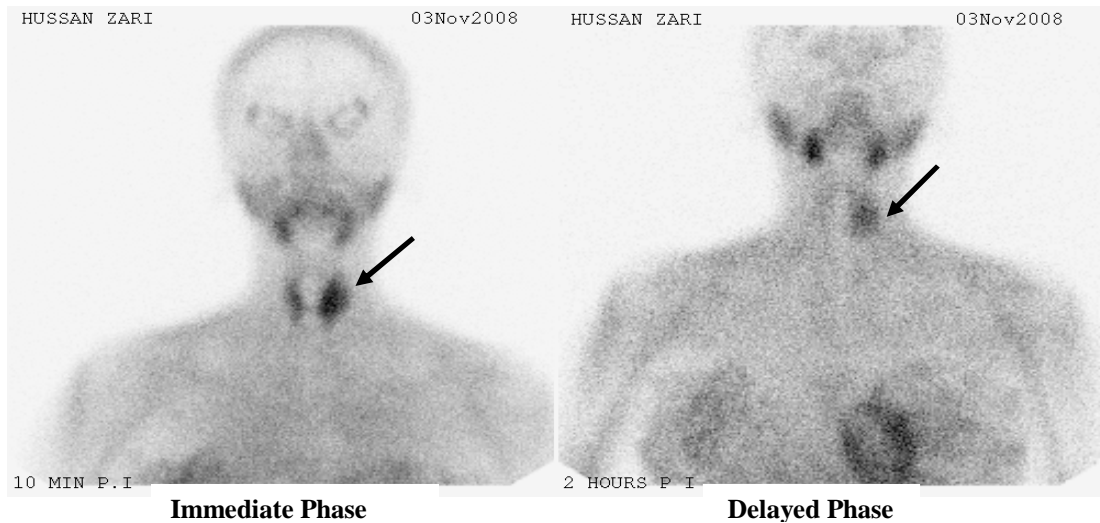

Figure-2: Dual Phase MIBI Parathyroid Scintigraphy showing persistent in left thyroid

A focal area of tracer uptake was appreciated in lower pole of left thyroidal lobe, which was persistent on delayed images (Figure-2). So after confirmation of parathyroid adenoma, treatment strategy was planned and ultrasound guided percutaneous ablation of adenoma was done with absolute alcohol. Patient was asked for follow up after 03 months with serum calcium, PTH level and ultrasound neck was repeated.

To our expectation results showed decline in serum calcium from 18 to 8.5 mg/dl and PTH from 969–311pg/ml. Also the size of adenoma was reduced to 20.6×10.3 mm along with markedly reduces in vascularity.

DISCUSSION

Tc-99m MIBI scintigraphy is an effective technique for preoperative localizing hyper-functioning parathyroid tissue accurately in 85% to 98% and is cost effective.⁶ Neck ultrasound adds in diagnostic accuracy.

Percutaneous ethanol injection (PEI) has been used effectively in treatment of primary or

secondary parathyroid adenomas hepatocellular carcinomas, metastatic liver lesions and in some cases of autonomous functioning thyroid nodules.⁷

Although the treatment of choice for symptomatic primary hyper parathyroid patients is surgery with a success rate of 95% and a complication rate of 1-2% however few patients do not full fill surgical criteria or have some underlying co morbidity that prohibit surgery. Percutaneous ethanol injection for parathyroid glands can be applied effectively in selected cases when surgery is unadvisable either for technical reasons (e.g., recurrence of hyperplastic glands in the neck after subtotal surgery or intrathyroidal parathyroid tumors or the poor clinical state of the patient. Ultrasound guided percutaneous ablation of parathyroid adenoma with absolute alcohol is a least invasive alternative therapeutic procedure. However percutaneous ethanol injection (PEI) needs further modification in standard procedure so as to reduce limit complications like incomplete necrosis and spillage of alcohol in surrounding tissues.

REFERENCES

1. Heath H III, Hobson SF, Kennedy MA. Primary hyperparathyroidism: incidence, morbidity and potential economic impact in a community. *N Engl J Med.* 1980;302:189-93.
2. Giardino A, Rubello D, Casara D. New trends in parathyroid scintigraphy. *Eur Nucl Med* 2001;28:1409-20.
3. Palestro CJ, Tomas MB, Tronco GG. Radionuclide imaging of the parathyroid glands. *Sem Nucl Med.* 2005; 35; 266-276.
4. McHenry CR, Lee K, Saadey J, Neumann DR, Esselstyn CB Jr. Parathyroid localization with technetium-99m-sestamibi: a prospective evaluation. *J Am Coll Surg* 1996;183:25-30.
5. Solbiati L, Montali C, Croce F, Bellotti E, Ciangrande A, Ravetto C. Parathyroid tumor detected by fine-needle aspiration biopsy under ultrasonic guidance. *Radiology* 1983;148:793-7.
6. Majors JD, Burke GJ, Mansberger AR Jr, Wei JP. Technetium-99m sestamibi scan for localizing abnormal parathyroid glands after previous neck operations: preliminary experience in reoperative cases. *South Med J* 1995;88:327-30
7. Solbiati L, Giangrande A, De Pra L, Bellotti E, Cantu` P, Ravetto C. Percutaneous ethanol injection of parathyroid tumors under US guidance: treatment for secondary hyperparathyroidism. *Radiology* 1985;155:607-10.

Address for Correspondent:

Dr. Shakil Ahmad, Head Nuclear Medicine, Department of Nuclear Medicine, Institute of Nuclear Medicine, Oncology and Radiotherapy (INOR), Mansehra Road Abbottabad.

Email: drshakilahmad@yahoo.com