

URBACH-WIETHE DISEASE: EXPERIENCE AT A TERTIARY CARE HOSPITAL IN ABBOTTABAD, PAKISTAN

Javeria, *Samiullah, Marium, Neelofar, *Fatima Samad **Ghulam Nabi, Saadia Ghazal

Ayub Medical College and Teaching Hospital Abbottabad, *The Aga Khan University Karachi, **Women Medical College Abbottabad

Background: Urbach-Wiethe disease (Lipoid Proteinosis) is a rare autosomal recessive disorder characterized by the deposition of an eosinophilic hyaline-like material in the skin, larynx, mucous membranes, brain, and other internal organs. **Methods:** A survey of one year duration was carried out prospectively at the Department of Dermatology, Ayub Teaching Hospital Abbottabad to document cases of lipoid proteinosis. Cases were selected from the outpatients department on the basis of clinical presentation and were subjected to detailed examination and investigations after admission. **Results:** Five cases were diagnosed as suffering from Lipoid Proteinosis over the study period. All had typical features of hoarseness, skin lesions and tongue involvement. All were born of consanguineous parents. Three (60.0%) cases also gave a history of involvement of other family members, particularly cousins. **Conclusion:** This rare disease occurs in Hazara Division of North West Frontier Province of Pakistan with an as yet undetermined frequency and clinical suspicion is warranted to diagnose cases with the typical presentation.

Key Words: Lipoid proteinosis, Urbach-Wiethe disease, Hyalinosis cutis et mucosae, Hoarseness

INTRODUCTION

Lipoid proteinosis (LP) was first described by a Viennese dermatologist Urbach and an otorhinolaryngologist, Wiethe, in 1929,¹ originally using the term 'lipoidosis cutis et mucosae'. This autosomal recessive disorder presents in early infancy with hoarseness, followed by pox-like and acneiform scars, along with infiltration and thickening of the skin and certain mucous membranes. Clinical presentation includes laryngeal infiltration leading to hoarseness. A characteristic finding is beaded papules along the eyelid margins.² Other mucocutaneous changes may include thickening of the tongue and frenulum, blisters, warty skin papules, scarring, alopecia, nail dystrophy and dental anomalies.³ Extracutaneous features may comprise of epilepsy and neuropsychiatric abnormalities, sometimes in association with calcification in the temporal lobes or hippocampi.³⁻⁵ Over 250 cases of this rare disorder have been described;⁶ occurrence of lipoid proteinosis in siblings is very rare.⁷

MATERIAL AND METHODS

The study was conducted at the Department of Dermatology, Ayub Teaching Hospital Abbottabad, Pakistan to document cases of lipoid proteinosis that were diagnosed and treated over a period of one year from September 2004 to October 2005. The cases were selected from the Dermatology Outpatient Department (OPD); the first case presented in September 2004 while other cases presented prospectively and were diagnosed during the study period.

Diagnosis was based on the clinical features, i.e., typical skin lesions, hoarseness of voice, changes in the tongue and oral cavity and beaded appearance of eyelid margins. Selected cases were admitted to the Dermatology ward and subjected to detailed

examination and investigations. Laryngeal examination was performed by consultation with the Department of Oto-Rhino-Laryngology of the Ayub Teaching Hospital.

RESULTS

A total of five cases presented during the study period. These included 4 (80.0%) females and 1 (20.0%) male patient (M:F ratio 1:4). The ages ranged from 5 years to 52 years, while mean age was 21.20 ± 18.5 years. All 5 cases were born of consanguineous parents and had very early ages of onset of disease, ranging from at birth to 10 years. Initial symptom of the disease was hoarseness of voice in 2 (40.0%) cases, combined hoarseness and skin lesions in 2 (40.0%) cases and only skin lesions in 1 (20.0%) case. The skin lesions were described as recurrent vesicles or blisters which healed later on by scarring and pock marks. At presentation, all 5 cases had fresh and old skin lesions evident as vesicles, blisters, waxy macules and papules and scars from previous healed lesions. Hoarseness of voice was present in all 5 cases as well. Oral examination showed that the tongue had firm to woody hard consistency on palpation and also limitation to protrusion from the mouth. Two cases (40.0%) also had ulcerations on the tongue. A beaded appearance of the eyelid margins was noticed in 3 (60.0%) of cases; it was not present in the two cases of younger ages (5 and 10 years of age). Three patients (60.0%) gave a family history of involvement of cousins and their siblings or other relatives with similar disease, including some members who died of it. One case had a maternal uncle's daughter with similar disease. The second case had a paternal cousin with similar disease since infancy, born of consanguineous parents; his elder brother also had the same disease and died of it. The third case had a maternal cousin with similar skin lesions; he also suffered from epilepsy and died at the age of 25 years.

Her brother's son aged 12 years has similar skin disease. Her brother's wife, who is also paternal cousin, has two nephews aged 9 and 6 years with same symptoms.

The typical clinical features are presented in the photographs below.

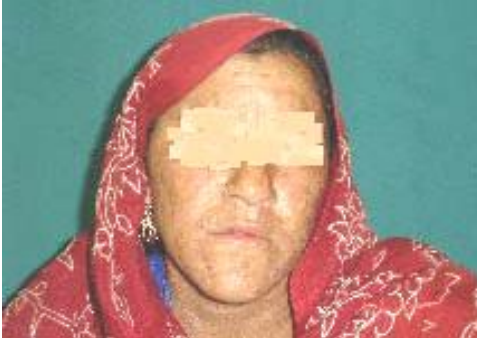

Figure-1: Acneiform lesions and scars on face.

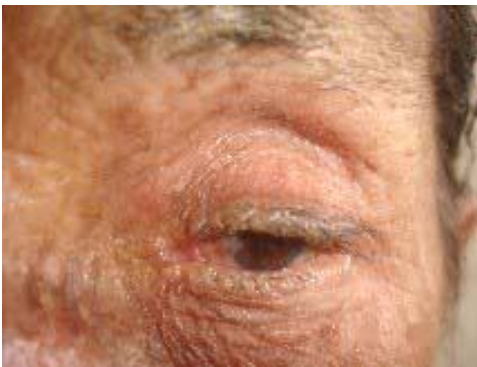

Figure-2: Beaded appearance of both eyelid margins

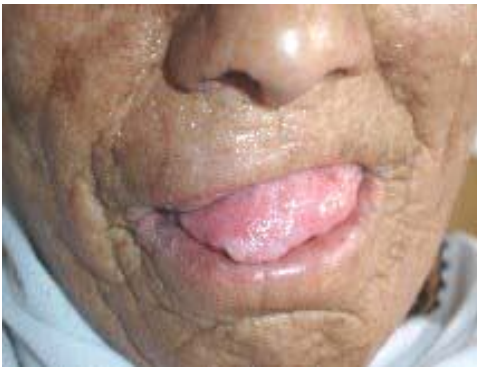

Figure-3: Limitation of tongue protrusion

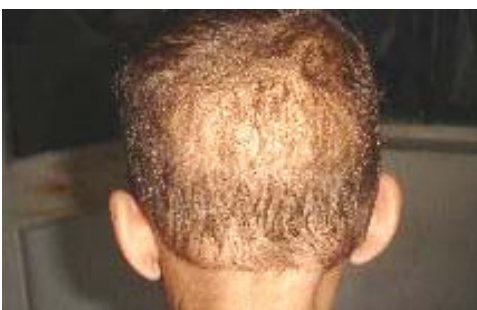

Figure-4: Sparse and thin hair on scalp

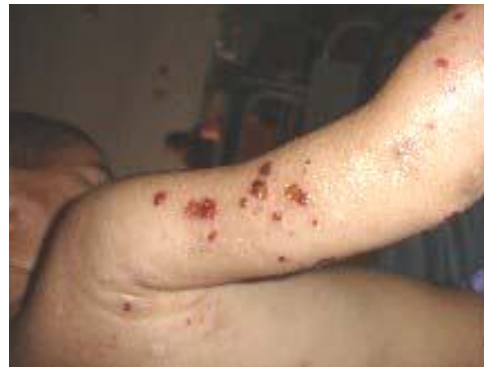

Figure-5: Vesicles and blisters on body

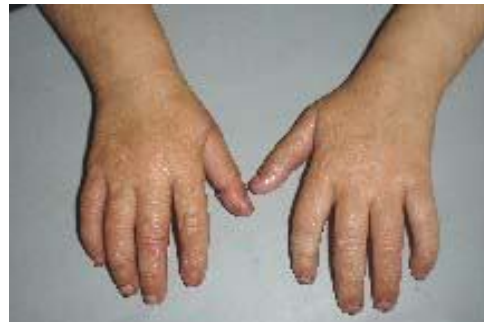

Figure-6: Claw like hands

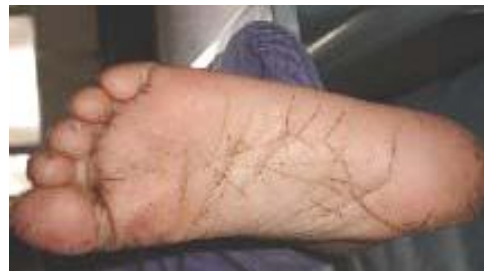

Figure-7: Deep creases on soles of feet

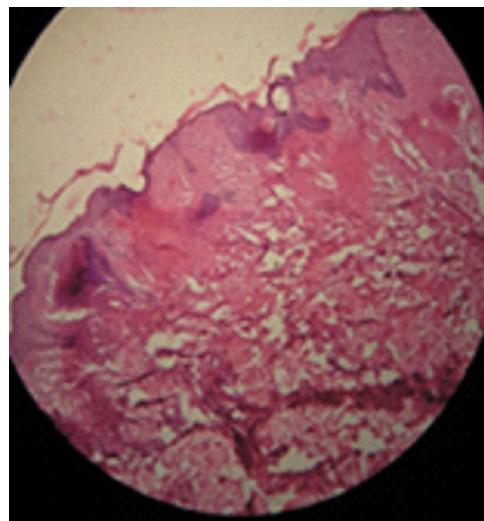


Figure-8: Microscopic view

DISCUSSION

Lipoid proteinosis (LP), also known as *Urbach-Wiethe disease* and *hyalinosis cutis et mucosae* (OMIM 247100), is a rare, autosomal-recessively inherited disorder. Heterozygous individuals have a normal phenotype, and they may have irregular dentition. It is typified by hoarseness from early years, along with a variety of cutaneous appearances (acneiform scarring, waxy papules, eyelid beading, etc.) and extra cutaneous expressions from incursion of hyaline-like material in the skin, larynx, and various organs.⁸

Clinically a child with a feeble or hoarse cry will be brought by parents.

Skin lesions will emerge within first year of life or may become visible later on. Infant may have regular milestones or have behavioural and learning dilemma. Seizures may possibly arise in case of hyaline deposits in central nervous system. Hyaline deposits in affected organs are the possible reason of positive findings at physical examination. Oral cavity shows several papules on the tongue, frenulum, lips, resulting in inability of the tongue to protrude out of the mouth which is a valuable diagnostic sign. The tongue feels hard, with a woody induration and shows frequent ulcerations. Unclean dental hygiene commences by dryness of mouth associated with infiltration and obstruction of the parotid duct and causes periodic parotitis. hypoplasia or aplasia of the lateral incisors and premolars teeth can occur as dental anomalies.

Early on skin signs include repeated vesicles, bullae, and hemorrhagic crusts around mucous membranes and on the skin, predominantly the face and distal extremities are involved. Extremities may show nail dystrophy and claw appearance of hands. Skin lesions heal with ice-pick scarring. Later on in adolescence skin becomes yellow, thickened and waxy in texture. Papules, plaques, and nodules crop up on the face, axillae, and scrotum which overlap with hyaline deposits in the dermis. On the elbows, knees, and sites of trauma, verrucous lesions resembling xanthomas may arise. Development of beaded papules along the eyelid margin (moniliform blepharitis) is the hallmark of lipoid proteinosis. Hair changes show patchy alopecia of scalp.

Complications include severe involvement of larynx and vocal cords leading to respiratory difficulty. Calcifications of the temporal lobe or hippocampi which becomes visible as bean-shaped opacities on skull radiography may give rise to epilepsy, mental retardation, and other neuropsychiatric illnesses.⁹

The specific pathogenesis is unidentified but there are two postulates. An eosinophilic, hyaline material fibroblastic in origin is deposited in all

affected organs, although it is a primary or secondary phenomenon is unknown. The fibroblastic origin of hyaline material suggests that lipoid proteinosis is primarily a lysosomal disease. However other studies reveal disturbance in collagen synthesis, as evident by decrease in the ratio of type-1 to type-3 collagen. The decrease in mRNA for type-1 procollagen results in underproduction of fibrous collagens and an increase in mRNA for type-4 procollagen causes an overproduction of basement membrane collagens, which is likely to deposit in the skin and various organs, predisposing to the disease.^{6,10,11}

Chromosomal mapping show involvement of chromosome 1q21 and pathogenetic loss-of-function is due to reduced expression of the extracellular matrix protein 1 (*ECM-1*) gene.⁶

Histologically, LP is characterized by deposition of PAS-positive, diastase-resistant hyaline. Basement membrane thickening at the dermo-epidermal junction, papillary dermis, surrounding blood vessels, and around adnexal epithelia especially sweat gland coils can be seen.¹²

Immunofluorescent labelling with anti type 4 collagen antibody shows bright thick bands of staining at the dermo-epidermal junction and around blood vessels consistent with basement membrane thickening.¹³ Ultrastructural examination reveals circular rings of surplus basement membrane surrounding blood vessels, and asymmetrical reduplication of lamina densa at dermo-epidermal junction resulting in onion-skin appearance.¹⁰ The only finding in laboratory studies that is abnormal with some consistency is an elevation in the erythrocyte sedimentation rate (ESR), which is believed to be caused by increased alpha-globulin and beta-globulin production.

LP needs to be differentiated from erythropoietic protoporphyria (EPP), a condition characterized by skin involvement confined to sun-exposed areas, and associated with photosensitivity. EPP also has a deposition of PAS-positive material, however it is less dense around blood vessels and never occurs around sweat gland coils. LP can also be differentiated histologically from amyloidosis and xanthomas, two other diseases associated with deposition of material in the eyelids.^{14,16}

This disease has a fluctuating course; although there have been many therapeutic trials in lipoid proteinosis but the treatment of this condition remains unsatisfactory. The treatment should include patient education and parents should be told about the risk of having affected offspring. Medical treatment includes oral steroids, dimethyl sulphoxide,¹² intralesional heparin, and etretinate.⁶ Surgical care involves resection of vocal cord papules in improving vocal quality. Dermabrasion may improve the

appearance of skin lesions. The goal of treatment is to reduce morbidity and prevent complications.

The finding of five cases of this disease with associated involvement of other members of the family tree during a one year study periods warrants a survey of the presence of this condition in Hazara; this region is well known for centuries of isolated habitation and intermarriages are commonplace. Clinical suspicion is warranted for all cases presenting in the Dermatology or Oto Rhino Laryngology Departments or to general practitioners in this area. Preventive aspects would include pedigree analysis and carrier detection followed by genetic marriage counselling.

REFERENCES

1. Urbach E, Wieth C. Lipoidosis cutis et mucosae. *Virchows Arch A Pathol Pathol Anat* 1929;273:285–319.
2. Dinakaran S, Desai SP, Palmer IR, Parsons MA. Lipoid proteinosis: clinical features and electron microscopic study. *Eye* 2001;15:666–8.
3. Hofer P. Urbach Wieth disease (lipoglycoproteinosis; lipoid proteinosis; hyalinosis cutis et mucosae). A review. *Acta Derm Venereol (Suppl)* (Stockh) 1973;53:1–52.
4. Friedman L, Mathews RD, Swanepoel PD. Radiographic and computed tomographic findings in lipoid proteinosis. A case report. *S Afr Med J* 1984;65:734–5.
5. Kleinert R, Cervos-Navarro J, Kleinert G, Walter GF, Steiner H. Predominantly cerebral manifestation in Urbach–Wieth's syndrome (lipoid proteinosis cutis et mucosae): a clinical and pathomorphological study. *Clin. Neuropathol* 1987;6:43–5.
6. Hamada T. Lipoid proteinosis. *Clin Exp Dermatol* 2002;27:624–9.
7. Sethuraman G, Tejasvi T, Khaitan BK, Handa KK, Rao S, Singh MK *et al*. Lipoid Proteinosis in two siblings: A report from India. *J Dermatol* 2003;30:562–5.
8. Black MM. Lipoid Proteinosis; Metabolic and nutritional disorders. *In: Champion RH, Burton JL, Burns DA, Breathnach SM, eds. Rook/Wilkinson/Ebling Textbook of Dermatology*, 6th edition, Oxford: Blackwell Science, 1998;p. 2460–2.
9. Ramsey ML, Tschen JA, Wolf JE. Lipoid proteinosis. *Int J Dermatol* 1985;24:230–2.
10. Moy LS, Moy RL, Matsuoka LY, Ohta A, Uitto J. Lipoid proteinosis: Ultrastructural and biochemical studies. *J Am Acad Dermatol* 1987;16:1193–1201.
11. Newton JA, Rasbridge S, Temple A, Pope FM, Black MM, McKee P. Lipoid proteinosis-new immunopathological observations. *Clin Exp Dermatol* 1991;16:350–4.
12. Touart DM, Sau P. Cutaneous deposition diseases. (Part 1). *J Am Acad Dermatol* 1998;39:149–71.
13. Aroni K, Lazaris AC, Papadimitriou K, Paraskevaki H, Davaris PS. Lipoid proteinosis of the oral mucosa: case report and review of literature. *Pathol Res Pract* 1998;194:855–9.
14. Wong CK, Lin CS. Remarkable response to oral dimethyl sulphoxide. *Br J Dermatol* 1998;119:541–4.
15. Bozdogan KE, Gul Y, Karaman A. Lipoid proteinosis. *Int J Dermatol* 2000;39:203–4.

Address for Correspondence:

Dr. Samiullah, 65/3 Kaghan Colony Abbottabad, Pakistan. Tel: +92-992-380822, Cell +92-321-9804099

Email: Samiullah.nabi@gmail.com