

CLINICOHISTOLOGICAL PATTERN OF OVARIAN TUMOURS IN PESHAWAR REGION

Sumaira Yasmin, Aiman Yasmin, Mohammad Asif*

Department of Obstetrics and Gynaecology, Postgraduate Medical Institute, Lady Reading Hospital, Peshawar, *Public Health, UNFPA, Peshawar, Pakistan

Background: Ovarian tumours are one of the major health problems confronting the general practitioners in general and gynaecologists in particular. Ovarian tumours may either be asymptomatic, found on the routine ultrasound examination or symptoms may be vague till the patient has an acute emergency like torsion or rupture of a benign cyst. The worst is late presentation of a malignant ovarian tumour. There is marked variation in the presentation of the tumour as well as in histological types. This study was undertaken to analyse modes of presentation and various histopathological patterns of ovarian tumours. **Methods:** This study was conducted from 1st January, 2002 to 31st December, 2002, in Gynaecology 'A' Unit, Lady Reading Hospital (LRH) Peshawar. After admitting patients with ovarian tumours a detailed case history was taken followed by thorough clinical examination. All the relevant details were recorded using the questionnaire. Patients were investigated after performing various surgical procedures; the specimens of ovarian tumours were subjected to Histopathological examination in the histopathology section, Lady Reading Hospital, Peshawar. **Results:** Amongst the total numbers of 5732 gynaecological admissions during study period the total numbers of ovarian tumours were sixty-eight. Out of which benign ovarian tumours were 61 (89.71%) and malignant ovarian tumours were 7 (10.29%) There were no tumours with borderline malignancy. The commonest histological pattern observed in the study was epithelial tumours (76.5%) including both benign and malignant tumours. The commonest benign tumour was serous cyst adenoma (24%) followed by mature cystic teratoma (18%). Common malignant ovarian tumours were granulosa cell tumours and Endometrioid carcinoma (each 28.5%). **Conclusion:** Epithelial tumours are the commonest variety of ovarian tumours followed by Germ cell tumours. The histological type of ovarian tumour correlates with the prognosis of the tumour.

Keywords: Ovarian tumours, teratoma, adenoma, cystadenoma, metastatic, neoplasm

INTRODUCTION

Diverse histopathologies are common in ovarian tumours reflecting the different cell origins of the tumours. Exact incidence in Pakistan is not known but ovarian cancer is the fourth most common cancer among females of Pakistan and continues to present at an advanced stage.¹ In eastern India, the fourth most frequent reported malignancy in females was ovarian.² Asian countries and Japan have rates of 2–6.5 new cases per 100,000 women per year.³ Ovarian carcinoma represents the sixth most common female cancer and the fourth leading cause of death due to cancers in women.⁴ Benign ovarian cysts may occur at any point in the life but they are most common during childbearing age and constitute about 90% of ovarian tumours.⁵ Most benign tumours are cystic and finding of solid elements make malignancy more likely. The most recent Surveillance, Epidemiology and End Results (SEER) calculations of lifetime risk for ovarian cancer are that 1 in 55 women will develop ovarian cancer over their lifetime⁶ Ovarian tumours are generally difficult to detect until they are advanced in stage or size, as the symptoms are vague and manifest over time.

Determination of various histologic patterns of ovarian tumours is very important in diagnosis as well as prognosis of ovarian tumours. Prognosis of

the tumours can also be predicted from the degree of differentiation of the tumours. The stage and laterality of the tumour also indicates their nature for example, tumours in the sex cord stromal category are almost always confined to a single ovary. On the other hand, approximately 65% of the metastatic tumours are bilateral. In this study we tried to find out the histopathological patterns which are more prevalent in our population and whether they are significantly different from other populations.

PATIENTS AND METHODS

This case series cover one year period starting from 1st January 2002 to 31st December 2002 at Gynaecology Unit LRH, Peshawar. All admitted cases diagnosed as ovarian tumours (Benign and malignant) were included in the study. The diagnosis of ovarian tumour is based on histopathology conducted in the histopathology laboratory of LRH. This was a descriptive study describing the various clinical presentations of ovarian tumours and their histopathological patterns. Patients with abdomino-pelvic mass other than that of ovarian tumours or metastatic tumours to the ovaries were excluded from the study. The acquired data was analyzed using the descriptive statistics. Frequency of the ovarian tumours (benign and malignant) was

determined and various clinical presentations of ovarian tumours were documented.

RESULTS

Total numbers of gynaecological admissions during the study period were (5732). Total numbers of ovarian tumours studied in this one year period were 68. Out of which benign ovarian tumours were 61 (89.71%) and malignant ovarian tumours were 7 (10.29%)

There were no tumours with borderline malignancy. The commonest histological patterns observed in the study were epithelial tumours (76.5%) including both benign and malignant epithelial tumours. The frequency of different histopathological types of benign ovarian tumour showed that the commonest tumour was serous cyst adenoma (24%) followed by mature cystic teratoma (18%) (Figure-1) Common malignant ovarian tumours were granulosa cell tumours and endometriod carcinoma (each 28.5%) (Figure-2) the commonest presenting symptom was pain abdomen followed by mass abdomen (Table-1).

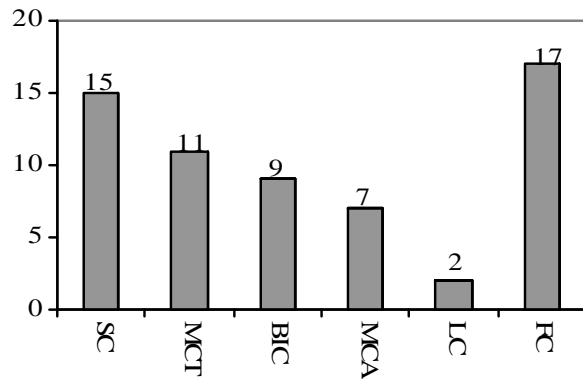


Figure-1: Frequency of Various histological types of Benign ovarian tumours (n=61)

SC= Serous cystadenoma, MCT=Mature cystic teratoma, BIC=Benign infitrated cyst, MCA=Mucinous cyst adenoma, LC=Luteal cyst, FC=Follicular cysts

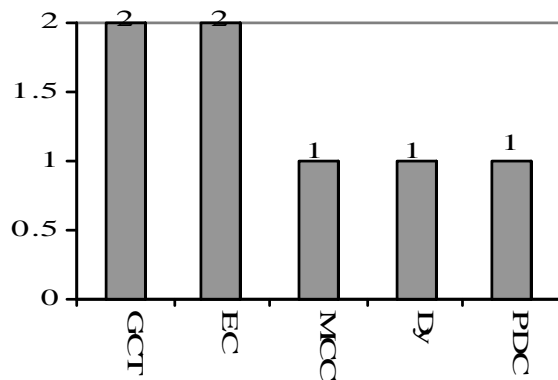


Figure-2: Frequency of various histological types of malignant ovarian tumours (n=7)

GCT=Granulosa cell tumors, EC=Endometriod Carcinoma, MCC=Mucinous Cystadeno Carcinoma, Dy=Dysgerminoma, PDC=Poor Differentiated Carcinoma

Table-1: Clinical presentation of the cases (n=68)

Symptoms	Cases	Percentage
Pain abdomen	48	70.59
Mass abdomen	10	14.71
Gastrointestinal disturbances	5	7.35
Menstrual	3	4.41
Urinary	2	2.94

DISCUSSION

Our study reveals that the Presentation of the ovarian tumour is variable. Some of the ovarian tumours may be incidentally diagnosed on ultrasound whereas others may present with acute abdominal pain. In our study the commonest presenting symptom was pain abdomen 48 (70.59%) followed by mass abdomen 10 (14.71%). The results comply well with a study carried out at Sir Ganga Ram and Myo Hospital Lahore⁷ in which abdominal pain was the commonest presenting complaint (59%) followed by abdominal mass/distension (37%). In contrast to another retrospective analysis by Jamal⁸ at Combined Military Hospital, Kharian the commonest mode of presentation was bleeding per vaginum, followed by pain abdomen, pelvic mass and gastric intestinal symptoms.

The exact nature of the ovarian tumour cannot be confirmed preoperatively just by clinical examination. Transvaginal ultrasonography has been recommended by the National Institute of Health as a preferred means of diagnosis.⁹ Ultrasonography has demonstrated usefulness in the detection of ovarian cancer in asymptomatic women, but its value for the detection of early-stage epithelial ovarian cancer in women of increased risk is uncertain.¹⁰ The microscopic appearance of the tumour is a must to find the histopathological pattern upon which further management rests.

Among histological types, the commonest category of the ovarian tumours encountered in our series was epithelial tumour followed by germ cell tumours. The most common benign tumour was serous cystadenoma 15 cases (24.59%) followed by mature cystic teratoma. Serous cystadenomas were shown the commonest by Thanikasalam among the Indians and teratomas were the commonest benign tumour among the Malays and Chinese¹¹. Serous tumours were found to be more common than mucinous. Similar results were reported by Prabhakar¹² in which serous tumours were the commonest followed by mucinous tumours. Some molecular and histological evidence suggests that mucinous epithelial ovarian cancers develop via a sequence from benign tumour through borderline tumour to invasive cancer which suggests the potential preventability of borderline and invasive mucinous ovarian cancer by surgical excision of identifiable precursor lesions.¹³ A retrospective study at Agha Khan University Hospital, Karachi¹⁴ from 1993–98 showed the

benign cystic teratoma to be the commonest benign tumour (35.17% of all benign tumours)

Pilli in Belgium recorded epithelial tumours to be the commonest variety constituting 70.9% of all the ovarian tumours followed by germ cell tumours (21.2%), sex cord stromal tumours (6.7%) and metastatic tumours (0.7%).¹⁵

Another observation in our study was that about (14.75%) of tumours were benign infarcted cysts of undetermined origin which form a fairly high proportion of the histopathological types. Such types of cysts are mostly non-neoplastic and these are the types where exact nature is very difficult to determine. Here at least malignancy is excluded and only then it is labelled as a simple infarcted cyst. The frequency of such infarcted cysts was found to be (7.2%) in a study by Shahid Jamal.⁸

Tumours in the borderline category are characterized by epithelial proliferation greater than that of the benign tumour but an absence of destructive invasion of the stroma¹⁶. In our series of patient we did not encounter any case of ovarian tumour with borderline malignancy. Among the non-neoplastic cysts follicular cysts were the commonest (27.8%). Follicular cysts and corpus luteal cysts were the commonest (80.2%) non-neoplastic lesions in a study by Gupta.¹⁷ Common malignant ovarian tumours were granulosa cell tumours and Endometrioid carcinoma (each 28.5%). An important aspect regarding histological pattern of malignant tumours is the degree of differentiation depicting the grade of tumour. The 5 year survival is associated with both stage and grade of disease. The 5 year survival rates for tumour stage I to IV are 85%, 71%, 41% and 22% respectively The survival rates with poorly differentiated tumours are significantly worse than with moderate or well differentiated tumours.

CONCLUSION

Epithelial ovarian tumours are the commonest which is similar to the Western & local data from other medical institutes. Germ cell tumours were next to epithelial ovarian tumours. Amongst malignant ovarian tumours late reporting is common and patients usually present in advanced stages of the

disease. The histological type of ovarian tumor correlates with the prognosis of the tumour.

REFERENCES

1. Parveen S, Ilyas N, Asghar S. Patterns of care for ovarian cancer: Patients at Institute of Nuclear Medicine and Oncology (INMOL) Lahore. *Specialist J Pak Med. Sci* 1999;15:209-15
2. SenU, Sankaranarayanan R, Mandal S, Romana AV, Parkin DM, Siddique M. Cancer patterns in Eastern India: The first report of Kolkata Cancer Registry. *Int J Cancer* 2002;100:86-91.
3. Murad A. Ovulation induction and ovarian tumours: the debate continues. *J Pak Med Assoc* 1998;48:353-6.
4. TortoleroL, Mitchell FM, Rhodes HE. Epidemiology and screening of ovarian cancer. *Obstet Gynaecol Clin North Am* 1994;21:63-75.
5. Day N.E, Krishnan E. Epidemiology of gynaecological cancers. *Gynaecology by Shaw R W. 2nd ed.* Edinburgh: Churchill Living Stone, 1997; p. 477-87.
6. Piver MS. Prophylactic Oophorectomy: Reducing the U.S. Death Rate from Epithelial Ovarian Cancer. *A Continuing Debate. Oncologist* 1996;1:326-30
7. Rashid S, Sarwar G, Ali A. A clinicopathological Study of ovarian cancer. Departments of Radiotherapy and oncology Sir Ganga Ram Hospital and Mayo Hospital Lahore. *J Pak Med Assoc* 1998;36:117-25.
8. Jamal S, Quddusi H, Mehmood A. A Clinico Histopathological analysis of 110 ovarian tumours. *Pak J Med Sci* 1997;14:19-23.
9. Sasaki H, Oda M, Ohmura M, Akiyama M, Liv C, ganes SV et al. Follow up of women with simple ovarian cysts detected by transvaginal sonography in the Tokyo matropoliton area. *Br J Obst Gynaecol* 1999; 415-20.
10. Fishman DA, Cohen L, Blank SV, Shulman L, Singh D, Bozorgi K *et al.* The role of ultrasound evaluation in the detection of early-stage epithelial ovarian cancer. *Am J Obstet Gynecol* 2005 ;192:1214-21.
11. Thanikasalam K, Ho CM, Adeed N, Shahidan MN, Azizah WK. LinkPattern of ovarian tumours among Malaysian women at General Hospital, Kuala Lumpur. *Med J Malaysia* 1992;47:139-46.
12. Prabarker, Maingi K. Ovarian tumours--prevalence in Punjab. *Indian J pathol Microbiol* 1989;32:276-81.
13. Jordan SJ, Green AC, Whiteman DC, Webb P M. Australian Ovarian Cancer Study Group. Risk factors for benign, borderline and invasive mucinous ovarian tumors: epidemiological evidence of a neoplastic continuum? *Gynecol Oncol* 2007;107:223-30.
14. Ahmed Z, Kiyani N, Hasan S. H, Muzaffar S. Gill M. S. Histological Patterns of ovarian neoplasia. *J Pak Med Assoc* 2000;50:416-9.
15. Pilli GS, Suneeta KP, Dhaded AV, Yenni VV. Ovarian tumours: a study of 282 cases: *J Indian Med Assoc* 2002;100:420, 423-4.
16. Barakat R.R. Borderline tumours of the ovary. *Obstet Gynaecol Clin North Am* 1994;21:93-105.
17. Gupta N, Bisht D, Agarwal AK, Sharma VK. Retrospective and respective study of ovarian tumours and tumour-like lesions: *Indian J Pathol Microbiol.* 2007;50(3):525-7.

Address for Correspondence:

Dr. Sumaira Yasmin, Department of Obstetrics and Gynaecology, Postgraduate Medical Institute, Lady Reading Hospital, Peshawar, Pakistan.