

REVERSE RADIAL ARTERY FLAP FOR SOFT TISSUE DEFECTS OF HAND IN PEDIATRIC AGE GROUP

Saeed Ashraf Cheema, Nabeela Talaat*

Department of Plastic Surgery, Services Institute of Medical Sciences and Services Hospital, Lahore, *Department of Paediatric Surgery, King Edward Medical University and Mayo Hospital, Lahore, Pakistan

Background: To highlight the usefulness of reverse radial artery flap in covering various soft tissue defects of hand in paediatric age group. **Methods:** A total of 16 reverse radial artery flaps were utilized in a period of three years to cover various soft tissue defects of hand for paediatric age group patients. The age ranged from 5–18 years. The two common causes of soft tissue defects in this series were mechanical trauma and fireworks trauma with five cases in each group. Three of the cases were burn victims and other two presented with earth quake injuries. One patient had wound because of road traffic accident. Soft tissue defects of palm were covered with this flap in eight cases while in three cases it was wrapped around the thumb. First web space defects were covered with this flap in two cases. Two cases required coverage of amputation stump at transmetacarpal level and yet another required a big flap to cover the soft tissue defects at palm, dorsum and thumb. Donor site was covered with split skin graft in all cases but one, which was closed primarily. **Results:** We had partial loss of flap in one case. Grafted donor sites healed uneventfully and were quite acceptable to the patients in due course of time. **Conclusion:** Reverse radial artery flap has a quite long arc of rotation which brings it great ease to cover the soft tissue defects of various areas of hand like palm, dorsum, first web space and thumb.

Keywords: Reverse radial artery flap, Hand injuries, Paediatric hand trauma

INTRODUCTION

Hand trauma is quite common in our setup. It is unfortunate that quite a big number of sufferers are in paediatric age group. Common aetiologies in this age group include fire works injuries, house hold burns and mechanical trauma.¹

Dealing with fireworks and various mechanical instruments requires a lot of care even by the adults. Involvement of paediatric age group in such activities in itself should be quite objectionable or at least under high safety measures. These safety measures in our society are, in general, either completely overlooked or exist at minimum levels. As a result, injuries due to these aetiologies lead to extensive defects of hand. Moreover, mechanical injuries are more severe as they usually combine the elements of cutting, crushing and avulsion.^{2,3}

Multiple options of local, regional and distant flaps exist to cover the soft tissue defects of hand injuries.⁴⁻⁸

This article evaluates the role of reverse radial artery flap to cover the soft tissue defects of hand.

MATERIAL AND METHODS

Patients having various soft tissue defects of hand covered with radial flap were included in this study. The study was carried out at the Department of Plastic Surgery, Services Hospital Lahore, during Jan 2004–Dec 2006. Defects arising from various aetiologies and at various aspects of hand were covered with this flap. Radial flap was found most suitable option in all these cases. Conventional reverse radial flap was used in all the cases. Allen's test was performed preoperatively to confirm the continuity of palmar arch. Again during the operation, once the flap has been raised, flow through

palmar arch was confirmed by applying clamp on the proximal end of radial artery and only then the artery was divided. In majority of the cases flap was tunnelled to the defect site. Only in three of the cases where subcutaneous tunnel was not found satisfactory, it was completely divided. Donor site was covered with split skin graft in all cases but one, which was closed primarily.

RESULTS

Sixteen cases of hand trauma were provided soft tissue cover with reverse radial artery flap in a period of three years. Fifteen out of them were males. Mechanical trauma and fireworks trauma were the two common aetiologies with five cases in each group. One case had post burn ulcers while other two had defects arising after the release of post burn contractures. Two patients presented with earth quake injuries. One case had defect as result of road traffic injury. Most common soft tissue defects were in the area of palm and there were eight cases in his group while in three cases flap was wrapped around the thumb. Web space defects were covered with this flap in two cases. Two cases required coverage of amputation stump at transmetacarpal level (Figure: 1–3) and yet another required a big flap to cover the soft tissue defects at palm, dorsum and thumb (Figure: 4–7). There was partial loss of one flap and rest of all the flaps in this series survived completely. Skin grafts at donor site were taken well. Although not reported by the patients but four of them were not satisfied with the colour match of the grafted area on enquiry. The difference of colour at grafted areas improved in the later follow ups. No neuroma or area of numbness was reported. Most common problem was that of contracture formation at the suture lines. (Figure-6) Three of these cases required release of contracture at later stage.

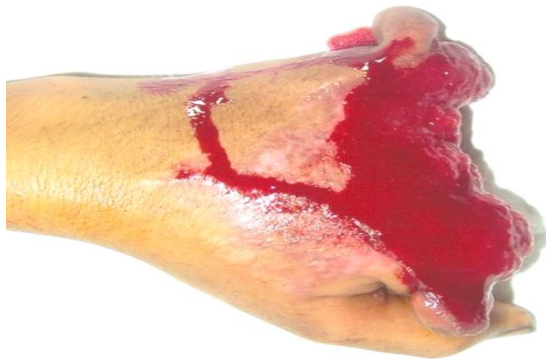

Figure-1: Injury at transmetacarpal joint level caused by minced meat machine.

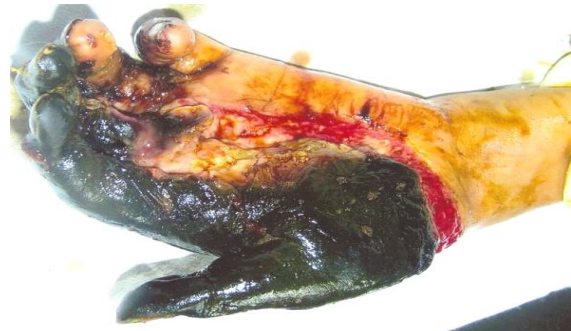

Figure-4: A fifteen year old patient with sugarcane crusher injury of left hand.

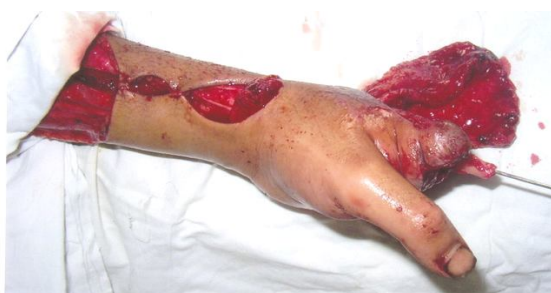

Figure-2: Fourth metacarpal bone utilized to lengthen the stump of index finger with reverse radial artery flap ready to cover the whole of the wound as well as bone graft

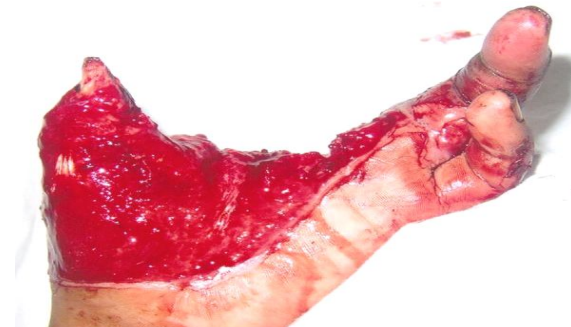

Figure-5: Same patient after debridement of the wound

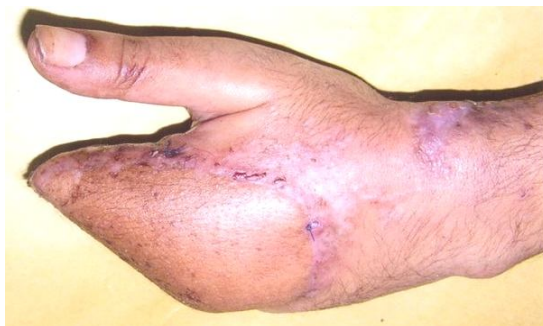

Figure-3: Same hand on fifteenth post operative day

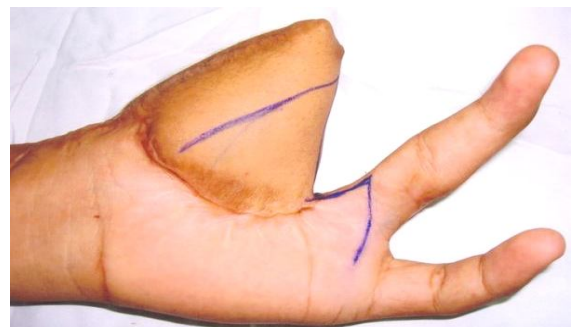


Figure-6: Six months follow up of the same patient. Reverse radial artery flap was utilized to cover the soft tissue defect. It also shows the opposing z plasties to release the contracture and deepen the first web

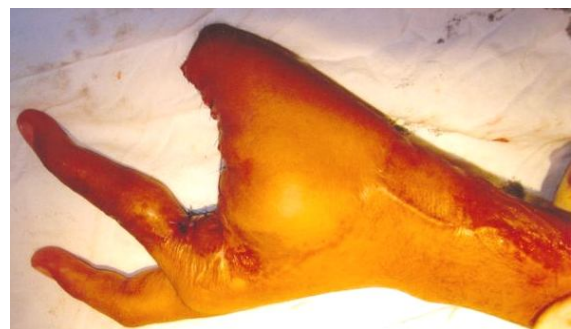

Figure-7: Same hand after the z plasty

DISCUSSION

Hand has very vital role to play in one's life as it acts like interphase between brain and external environment. Its normal function requires stable, sensate skin, maintenance of web spaces, soft pliable skin cover necessary to facilitate movements of intrinsic muscles, number of tendons and other structures passing under it. Grafts may provide cover to large defects of hand but are not always a reliable option if denuded tendons and bones are making most part of the wound. Also, grafts have a natural tendency of contractures and wrinkle formation and thus may cause hindrance in the function of hand at later stages.⁹

Table-1: Table showing the age range of the patients, aetiologies and areas of hand covered with the flap.

S. No.	Age/Sex	Aetiology	Area covered	S. No.	Age/Sex	Aetiology	Area covered
1	16/m	Mechanical trauma	Palm	9	10/m	Mechanical trauma	Stump at transmetacarpal level
2	15/m	Mechanical trauma	Palm	10	18/m	Mechanical trauma	Palm
3	12/m	Fireworks blast injury	1 st web space	11	8/m	Trauma	Palm & middle finger
4	17/m	Fireworks blast injury	Thumb	12	9/m	Trauma	Palm
5	15/m	Fireworks blast injury	Thumb	13	6/m	Electric burn injury	Thumb
6	11/m	Fireworks blast injury	Palm	14	11/m	Electric burn injury	Palm & 1 st web space
7	13/f	Burn injury	1 st web space	15	9/m	Burn injury	Palm
8	15/m	Mechanical trauma	Dorsum, palm, thumb	16	14/m	Road traffic accident	2 nd 3 rd web spaces

Hand has got number of local flaps available but their use is restricted to smaller wounds only. Use of distant flaps from chest, abdomen, opposite arm is commonly reported.^{5,6} Similarly groin flap has also been regularly used for various defects of hand.^{7,8}

However, distant flaps have some inherent problems as well. All of these are multistage procedures and not only they increase the length of hospitalization and economical burden of the patients but also tend to aggravate oedema and stiffness of hand due to immobilization of hand which is quite mandatory in most of these procedures. At times these flaps may be quite bulky thus necessitating debulking at later stage. Free tissue transfer may be a good solution for all these problems but has more sophisticated demands. Extensive preoperative evaluation, presence of adequate recipient vessels, availability of sophisticated equipment, know how with micro vascular techniques and sufficient time availability all make this treatment of choice less applicable in majority of patients in our most of the setups.¹⁰

On the other hand, few of the regional flaps are quite useful in extensive defects of hand. These include reverse radial artery flap, reverse ulnar artery flap and posterior interosseous artery flap.¹¹⁻¹⁵

Even among these options reverse radial flap is more outstanding in its certain qualities when compared with rest of the options. It has a long arc of rotation and thus it can be used to cover defects of palm, dorsum, and both ulnar and radial sides of hand along with web spaces and defects at transmetacarpal level. Flap itself is quite versatile and can be raised in varying sizes and depths. Quite extensive defects can be covered by this flap as whole of the skin area between the preaxial and postaxial borders of forearm starting from elbow to wrist can be elevated as a single flap. Flap can incorporate vascularised tendons of palmaris longus and brachioradialis as well as part of radius bone. Further benefits include ease of raising this flap which is quite dependable. Due to all these qualities this flap is also quite a good option for single staged reconstruction of thumb.¹⁶ It can also be de-syndactylised to cover the defects over fingers simultaneously.¹⁷

Present series once again highlights that in our setup most of the extensive soft tissue defects of hand originate due to aetiologies which are purely preventable as ten of the cases (56%) were result of mechanical trauma and fireworks injuries.

Most of the defects covered were in the region of palm. Flap successfully covered the defect at dorsum while in three of the case it was used to wrap around the reconstructed thumb. It was used to reconstruct first web space in three other cases. In one of the cases mechanical trauma resulted in amputation of all four fingers at metacarpophalangeal joints level. Patient refused the option of toe to finger transfer and the stump was covered with reverse radial flap. However, in an attempt to reconstruct and deepen the first web space fourth metacarpal bone was harvested and used to lengthen the stump at index finger and this whole complex was wrapped with reverse radial flap (Figure-2). This helped to lengthen the stump at index finger and increase the depth of first web and thus contributing towards a bit more functional hand (Figure-3).

Many a complications of reverse radial flap have been reported and they include circulatory embarrassment, malfunction of hand, or acute ischemia of hand.¹⁸

However, this series did not witness any of these complications. One very important step in this regard is checking the continuity of the palmar arch by Allen's test which was performed regularly in this series on every case preoperatively. Moreover, the patency of palmar arch was rechecked intraoperatively by clamping the radial artery just before its division and checking bleeding from the flap edges. Any anomaly of radial artery was also kept in mind while planning and raising this flap¹⁹ but again this series did not witness any significant anomaly in radial artery.

Instead, the most common complication in this series was contracture formation along the suture lines both at the recipient and donor sites. It needed release in three of the cases (Figure-6). This contracture formation may be prevented and reduced by avoiding a straight line scar and with regular massage of the suture lines. The cosmetic deformity at the donor site, particularly when flap is

fasciocutaneous, can be minimized by using a purely facial flap. Also the serial excision of the skin grafted area can help this problem. In this series none of the patients reported any concerns regarding the cosmetic deformity at donor site.

This series witnessed some of the extensive soft tissue defects of hand and this flap was successfully used to cover these defects (Figure-5).

It can be concluded that radial forearm flaps can be used to cover most of the defects at palm, dorsum, around thumb and the first web space. Preoperative psychological counselling of patients, evaluation of the patency of palmar arch and post operative physiotherapy of the donor site area remain the precautions to be taken into account while considering this flap as an option.

CONCLUSION

Reverse radial artery flap has a quite long arc of rotation which brings it great ease to cover the soft tissue defects of various areas of hand like palm, dorsum, first web space and thumb.

REFERENCES

1. Cheema SA. Patterns of hand injuries and reconstruction modalities. Esculapio. J Serv Inst Med Sci Lahore 2007;2(1):26-9.
2. Moss CJ. Machinery hazards. Ann Occup Hyg 1969;12(2):69-75.
3. Chari PS, Kharshiing W, Balakrishnan C. Wheat thresher hand injuries. Indian J Med Res 1975;63:829-32.
4. Medalie DA. Perforator-Based Forearm and Hand Adipofascial Flaps for the Coverage of Difficult Dorsal Hand Wounds. Ann Plast Surg 2002;48(5):477-83.
5. Kelleher JC, Sullivan JC, Baibak GI. Large compound axial vessel abdominal pedicle flap: indications for its use in surgery of the hand. Ortho Clin North Am 1970;1:227.
6. White WL. Flap grafts to upper extremity. Surg Clin North Am 1960;40:389-97.
7. McGregor IA, Jackson IT. The groin flap. Br J Plast Surg 1972;25:3-16.
8. Wray RC, Wise DM, Young VL, Weeks PM. The groin flap in severe hand injuries. Ann Plast Surg 1982;9:459-62.
9. Ragnell A. The Secondary contracting tendency of free skin grafts. Br J Plast Surg 1952;5:6-24.
10. Inoue G, Suzuki K. Arterialized venue flap for treating multiple skin defects of the hand. Plast Reconstr Surg 1993;91:299-302.
11. Soutar DS, Tanner NS. The radial forearm flap in the management of soft tissue injuries of the hand. Br J Plast Surg 1984;37:18-26.
12. Govila A, Sharma D. The radial forearm flap for reconstruction of the upper extremity. Plast Reconstr Surg 1990;86:920-7.
13. Angrigiani C, Grilli D, Dominikow D, Zancolli EA. Posterior interosseous reverse forearm flap: Experience with 80 consecutive cases. Plast Reconstr Surg 1993;92:285-93.
14. Kaufman MR, Jones NF. The Reverse radial forearm flap for soft tissue reconstruction of the wrist and hand. Tech Hand Up Extrem Surg. 2005;9(1):47-51.
15. Rogachefsky RA, Mendieta CG, Galpin P, Ouellette EA. Reverse radial forearm fascial flap for soft tissue coverage of hand and forearm wounds. J Hand Surg 2000;25(4):385-9.
16. Soutar DS, Tanner NSB. The radial forearm flap in the management of soft tissue injuries of the hand. Br J Plast Surg 1984;37:18-26.
17. Al-Qattan MM, Ziesmann M. Immediate de-syndactylization of the reverse radial forearm flap. The Journal of Hand Surgery 2000;25(1):61-4.
18. Jones BM, O'Brien CJ. Acute ischemia of the hand resulting from elevation of a radial forearm flap. Br J Plast Surg 1985;38:396-7.
19. Small JO, Millar R. The radial artery forearm flap: An anomaly of the radial artery. Br J Plast Surg 1985;38:501-3.

Address for Correspondence:

Dr. Saeed Ashraf Cheema, 34. Faisal Block, Azam Garden, Multan Road, Lahore, Pakistan. Cell: +92-300-8434042, +92-321-8434042

Email: sacheema2002@yahoo.com