

IMAGES IN MEDICINE

ORAL MUCOCELE (MUCOUS EXTRAVASATION CYST)

Thorakkal Shamim

Department of Dentistry, Government Taluk Head Quarters Hospital, Nilambur-679329, India

CASE

A 48-year-old Indian woman presented with a painless lower right lip swelling of size 1×1 cm for two years (Figure-1). The swelling was initially small and slowly increased its size. The overlying mucosa was normal. The swelling was superficial, bluish, fluctuant, soft and non-tender with diffuse margins. She could not recall an episode of trauma to the maxillofacial region. A biopsy was performed and showed areas of spilled mucin surrounded by a granulation tissue with infiltration of chronic inflammatory cells and foamy histiocytes. Dilated salivary gland ducts were also seen in the section (Figure-2). No recurrence was observed at 5 months follow-up examinations.

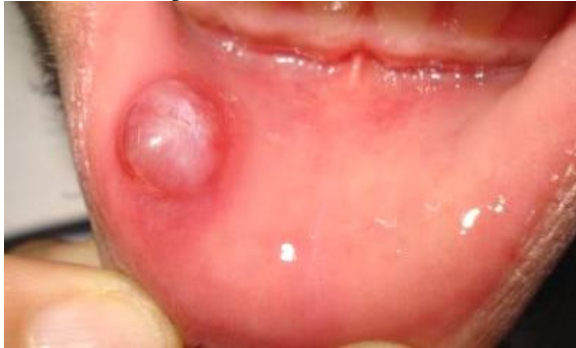

Figure – 1: Swelling on right lower lip

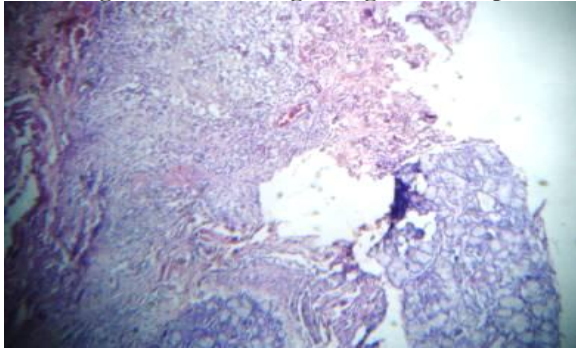


Figure – 2: Histopathology of the lesion

DISCUSSION

This report describes a lesion of the lower lip that was diagnosed by histologic examination as a mucocele or mucus extravasation phenomenon. Mucocele is a clinical term that applies to the mucous extravasation phenomenon.¹ The most common site for mucocele is

the lower lip followed by the buccal mucosa, ventral tongue, floor of the mouth and retromolar region.¹ Mucoceles typically appear as dome shaped mucosal swellings that can range from 1 or 2 mm to several cm in size.² It usually results from rupture of a salivary gland duct and spillage of mucin into the surrounding soft tissues.² Treatment of mucocele includes surgical excision with removal of the associated gland.³ The differential diagnoses for this lesion includes mucocele, epulis, salivary gland tumour, traumatic lesion and vesiculobullous lesion(mucous membrane pemphigoid).

Quiz

1. What is the diagnosis?
 - A. Mucocele (mucous extravasation cyst)
 - B. Salivary gland tumour
 - C. Vesiculobullous disorder
 - D. Traumatic lesion

Answer: (A) Mucocele (mucous extravasation cyst)

2. Describe the histopathologic features of this lesion (Figure-2).

Areas of spilled mucin surrounded by a granulation tissue with infiltration of chronic inflammatory cells and foamy histiocytes. Dilated salivary gland ducts were also seen in the section.

3. List out the differential diagnoses for this lesion.

Answer: Mucocele, epulis, salivary gland tumour, traumatic lesion, vesiculobullous lesion (mucous membrane pemphigoid).

4. Which is the most common site for mucocele?

- A. Lower lip
- B. Buccal mucosa
- C. Ventral tongue
- D. Floor of the mouth

Answer (A) Lower lip

5. What is the treatment of choice for mucocele?

Answer: Surgical excision with removal of associated gland.

REFERENCES

1. Regezi JA, Sciubba JJ, Jordan RCK. Oral pathology: clinical pathologic correlations.4th ed. St.Louis, Missouri: WB Saunders; 2003. p.183–5.
2. Neville BW,Damm DD, Allen CM, Bouquot JE. Oral and maxillofacial pathology.2nd ed. New Dehli: Reed Elsevier India Pvt Ltd; 2004. p.389–91.
3. Esmeli T, Lozada-Nur F, Epstein J.Common benign oral soft tissue masses. Dent Clin N Am 2005;49:223–40.

Address for Correspondence:

Dr. Thorakkal Shamim, BDS, MDS, Shangrila, Parappanangadi-676303, India. Tel: +91-9895447351

Email: shamu3duad@rediffmail.com